

# **Isolated Limb Perfusion for Unresectable Extremity Cutaneous Squamous Cell Carcinoma; an effective limb saving strategy**

Eva A. Huis in 't Veld, MD<sup>1, 2</sup>; Dirk J. Grünhagen, MD, PhD<sup>3</sup>; Jan P. Deroose, MD, PhD<sup>2,3</sup>; Tamar E.C. Nijsten, MD, PhD<sup>4</sup>; Michel W.J.M. Wouters, MD, PhD<sup>2</sup>; Cornelis Verhoef, MD, PhD<sup>3</sup>; Winan J. van Houdt MSc, MD, PhD<sup>1, 2</sup>; Andrew J. Hayes, MD, PhD<sup>1</sup>

1. Sarcoma and Skin Units, Department of Academic Surgery, Royal Marsden NHS Trust, London, United Kingdom
2. Department of Surgical Oncology, Netherlands Cancer Institute , Amsterdam, The Netherlands
3. Department of Surgical Oncology, Erasmus MC – Cancer Institute, Rotterdam, the Netherlands
4. Department of Dermatology, Erasmus MC, Rotterdam, The Netherlands

## ***Running title***

Isolated Limb Perfusion of Squamous Cell Carcinoma

Correspondence address

Eva A. Huis in 't Veld, MD<sup>1,2</sup>  
Department of Surgical Oncology,  
Netherlands Cancer Institute,  
Plesmanlaan 121, 1066CX, Amsterdam,  
The Netherlands  
e.huisintveld@nki.nl

## **Abstract**

**Background** A small minority of patients present with locally advanced cutaneous Squamous Cell Carcinoma (cSCC). The aim of this study was to evaluate the effectiveness of Tumor necrosis factor  $\alpha$  (TNF) and melphalan based isolated limb perfusion (TM-ILP) as a limb saving strategy for locally advanced extremity cSCC.

**Methods** A retrospective search from prospectively maintained databases at two tertiary referral centers was performed to identify patients treated with TM-ILP for locally advanced cSCC of an extremity between 2000 and 2015.

**Results** A total of 30 patients treated with TM-ILP for cSCC were identified, with a median age of 71 years (36-92) and 50% female. Response could not be evaluated in 3 patients. After a median follow up of 25 months, the overall response rate was 81% (n=22), with 16 patients having a complete response (CR, 59%). A total of 7 patients developed local recurrence, with a median time to recurrence of 9 months (Interquartile Range 7 – 10). Progressive disease was observed in 5 patients (19%). Limb salvage rate was 80%. The overall 2-year survival was 67%.

**Conclusions** TM-ILP should be considered as an option in patients with locally advanced cSCC in specialized centers, resulting in a high limb salvage rate.

## **Background**

Non-melanoma skin cancer (NMSC) is the most frequent human malignancy<sup>1, 2</sup> with an increasing incidence reaching epidemic proportions among Caucasians in Europe, America and Australia.<sup>3-8</sup> Approximately 80% of all NMSC are basal cell carcinomas (BCC) and 20% are cutaneous squamous cell carcinomas (cSCC).<sup>6-9</sup>

Usually cSCC presents as a localised lesion, for which various treatment strategies are available: wide surgical excision, Mohs surgery, cryosurgery, and radiation therapy. Margins of resection are an important prognostic factor for outcome<sup>10</sup> and the primary aim of surgery is to remove the tumor *in total* with adequate margins. However some patients will present with locally advanced disease. In such locally advanced cases, a radical resection to achieve negative surgical margins may lead to serious loss of limb function, or may even require an amputation.

Regional chemotherapy by hyperthermic isolated limb perfusion was introduced as a therapy to treat advanced extremity malignancies either as a standalone treatment or as a neo adjuvant treatment to down size a malignancy and facilitate function preserving surgery.<sup>11, 12</sup> Several reports show excellent response rates with tumor necrosis factor  $\alpha$  (TNF) and melphalan based isolated limb perfusion (TM-ILP) for both melanomas with multiple in transit metastases and for locally advanced soft tissue sarcomas.<sup>11, 13-15</sup> Likewise, large series show that TM-ILP is a safe procedure with only a limited local toxicity without severe systemic toxicity.<sup>16</sup> These observations led to the exploration of ILP for locally advanced cSCC of the extremities. This study aims to evaluate the effectiveness of TM-ILP as a limb saving strategy for locally advanced cSCCs in the extremities.

## **Methods**

### **Patients**

Between 2000 and 2015, all patients treated with TM-ILP for locally advanced cSCC were identified from a prospectively maintained database in one of the two tertiary referral hospitals: Erasmus MC - Cancer Institute, Rotterdam, the Netherlands, and Royal Marsden Hospital, London, United Kingdom. All patients were considered to be surgically treatable only by amputation or function disrupting ablative surgery because the extent of tumor affecting the limb. Unresectability of the tumor was based on the following factors: size, multifocality, number of recurrences, and tumor location (adherent to bones, blood vessels or nerves). All patients were discussed in a multidisciplinary tumor board. The majority of patients had chronic infected fungating tumors, and therefore almost all patients underwent TM-ILP with prophylactic systemic antibiotics.

## **Perfusion**

The ILP technique has been described extensively before.<sup>17</sup> Briefly, After heparinization, the surgeon isolated the targeted vessels from the systemic circulation and cannulated the vessels with silastic cannulae. The surgical approach for cannulation could either be at the inguinal, femoral, axillary, or brachial level depending on the location of the tumor. To prevent leakage a pneumatic tourniquet was used to compress collateral vessels. Leakage from the isolated circulation to the systemic circulation was measured continuously using technetium labelled albumin. A dose of 1 to 3 mg (arm) or 1 to 3 mg (leg) of recombinant TNF was injected as a bolus. The dose of melphalan ranged between 50 and 80 mg for the perfusion of a leg and between 25 and 60 mg for an arm based on volume of the limb or body weight.<sup>(16)</sup> After the perfusion, the limb was washed out.

## **Toxicity**

Acute regional toxicity after perfusion was classified according to Wieberdink *et al.*<sup>18</sup> Regional toxicity and systemic complications were evaluated during the hospital stay or during follow up visits.

## **Outcome**

The primary outcome measure was response to TM-ILP. Response was measured by clinical examination and scored following World Health Organisation criteria.<sup>19</sup> Time to local progression, systemic disease and overall survival were defined as time from ILP to the event. The secondary outcome measure was limb salvage after TM-ILP. TM-ILP could potentially be a curative treatment or a neoadjuvant therapy to downsize a tumor prior to radical function preserving resection. Both of these approaches were considered to be limb salvage strategies.

## **Statistical analysis**

In this retrospective review, survival analyses were performed using the Kaplan Meier method. Differences between groups were assessed by the Log-rank test, T-tests and Fisher exact tests. A p-value of 0.05 was considered significant. Confounders for local progression and overall survival (OS) were identified using univariate analysis. Only confounders with a p-value below 0.1 were subsequently included in a multivariate Cox regression. Factors explored were: age, gender, hospital of treatment, site and size of the tumor (<5cm, or >5cm). IBM SPSS statistics 24 was used for the statistical analyses.

## **Results**

### **Patients**

A total of 30 patients were treated with TM-ILP of which 15 (50%) were female. Median age at time of TM-ILP was 71 (Interquartile Range [IR] 62 - 79). Median follow up was 25 months (IR 10 - 36). TM-ILP was offered in 18 patients with primary disease (60%), in 10 patients with local recurrent cSCC (33%), and two patients were known to have systemic disease and underwent a palliative ILP (7%). Patient, tumor- and treatment characteristics are summarized in table 1.

### **Treatment outcome**

Response could be evaluated in 27 patients. In three patients response could not be evaluated because of, amputation (n=1), or death (n=2) within 3 months after ILP.

The overall response (OR) rate of these 27 patients was 81% (n=22). Sixteen patients had a complete response (CR, 59%) and 6 patients had a partial response (PR, 22%). An example of a complete response is depicted in figure 1. Five patients (19%) had progressive disease (PD) within 3 months after TM-ILP. No differences in tumor size (p=1,000), stage of disease

( $p=0,248$ ), number of tumors ( $p=0,246$ ) and tumor location ( $p=0.263$ ) were found between the different response groups (Table 2).

### **Surgical intervention**

Of all 30 patients, at least 19 patients were candidates for amputation before ILP. Of these patients, 13 patients did not need surgical intervention after ILP (68%), 1 patient needed resection (5%) and 5 needed amputations (26%).

Analysing all 30 patients, 12 patients eventually needed surgical intervention after TM-ILP (40%), which consisted of resection of tumor in 5 patients (17%), and amputation in 6 patients (20%)(fig. 2). One patient (3%) needed surgical intervention but refused.

Of the 5 patients who underwent a limb conserving resection of residual or remaining tumor, two patients underwent resection of residual tumor and the tumor was found to be 100% necrotic on histopathological analysis. Both of these patients were classified as CR. Two patients had PD with already metastatic disease at time of ILP. For these patients ILP was done with palliative intent because of intractable pain and/or uncontrollable wounds, but due to progression surgery was unavoidable. One patient had a clinical PR and underwent a surgical resection of residual tumor which demonstrated viable tumor on histopathological analysis.

Of the 6 patients who underwent an amputation after TM-ILP, one patient had an initial CR but subsequently needed amputation after development of local recurrence. After resection of the recurrence this patients suffered from severe wound healing problems and amputation was unavoidable. Three patients had an amputation because of PD, and one patient had a PR but still needed amputation. Finally, one patient needed amputation due to ischemia. The median time between TM-ILP and amputation in these 6 patients was 3 months (range 0-9).

### **Local progression**

Of the 27 patients whose response could be evaluated, five patients (19%) showed no response to TM-ILP and had immediate PD. Of all 30 patients, another 7 patients (23%) developed local progressive disease during follow up. The median time to local progression for these 7 patients was 9 months (IR 7 – 10) (table 3). The local progression free survival (PFS) was significantly longer in the CR group, compared to the PR group (Log-rank,  $p=0.018$ ), whereby the median PFS for both groups was not reached. None of the following factors were associated with duration of PFS: age ( $p=0.216$ ), gender ( $p=0.560$ ), hospital ( $p=0.187$ ), site ( $p=0.862$ ), and size of the tumor (<5cm, or >5cm,  $p=0.939$ ).

### **Systemic Metastasis**

A total of 3 patients in this cohort had lymph node metastases at time of ILP (10%) and were treated with lymph node dissection concurrent with ILP. In addition, 3 more patients (10%) developed lymph node metastases in the follow up and were treated with lymph node dissection with a median time to lymph node metastases of 4 months (range, 0-9)(table 3). Systemic metastases were present in two patients (7%) at time of ILP, while two more patients (7%) developed systemic disease during follow up: 3 and 21 months after ILP (table 3).

### **Overall survival**

Eighteen patients were alive at last follow up (60%) with a median follow up for this particular group of 30 months (IR 18 - 38). In 14 patients (47%) there was no evidence of disease at last follow-up. Twelve patients (40%) died during follow up, of whom 6 (20%) died of advanced disease, 2 (7%) of complications after surgery, and 4 (13%) of reasons not related to cSCC. Median OS was 54 months (95% CI: 20.4-87.6), with a 2 year survival of 67%.

Gender ( $p=0.187$ ), hospital ( $p=0.748$ ), site of cSCC ( $p=0.241$ ), and size of the tumor (<5cm, or >5cm,  $p=0.370$ ) did not influence overall survival.



## **Complications**

The vast majority of patients in this series did not experience serious local toxicity. In 25 patients (83%) Wieberdink I or II was observed and in four patients (13%) Wieberdink III. One patient (3%) underwent an amputation 9 days following TM-ILP (Wieberdink V) due to ischemia. Leakage to the systemic circulation was minimal in all procedures, in only one case a leakage of 5% was noted, while in all other cases leakage was 2% or lower. The thirty-day mortality following TM-ILP for advanced cSSC was 0, however, two patients died 66 and 71 days after perfusion. The first patient was admitted to the Intensive Care Unit with respiratory distress after his operation and eventually died of pneumonia and respiratory failure. This patient had severe comorbidity, including severe chronic pulmonary obstructive disease and pre-existing diabetic complications (renal failure and hypertension). The procedure of the second patient was complicated due to a rupture of the brachial artery that was cannulated for TM-ILP. The patient was re-operated in an outside hospital and a vascular prosthesis was inserted. The patient died two months after TM-ILP of septic complications caused by an infected vascular prosthesis.

## ***Discussion***

This unique multicentre experience of 30 TM-ILPs as treatment for locally advanced cSSC and demonstrates that TM-ILP is a valuable limb saving strategy in selected patients who would otherwise need an amputation or function disrupting ablative surgery. To our knowledge, this is the largest report on the outcome of ILP for locally advanced cSSC. With an overall response rate of 81%, a CR rate of 59%, and a limb salvage rate of 80%, this data shows that ILP is an effective treatment to obtain local control for locally advanced cutaneous squamous skin carcinoma. Almost half of the patients were free of disease at the end of follow up (n=14, 47%).

Reports in the literature of oncological outcomes for advanced unresectable cSCC treated by ILP or other modalities are rare. One small study reports a series of 12 ILPs treated at multiple centres for cSCC with comparable results to this study (CR of 67% and 75% limb salvage rate).<sup>20</sup>

Other treatment modalities described for advanced cSCC at any site include conventional cytotoxic chemotherapy, newer systemic therapies, radiotherapy, and combinations of these modalities.<sup>21-30</sup> There are a number of small case series of patients with advanced cSCC treated with cytotoxic chemotherapy usually involving cisplatin.<sup>22, 24, 25</sup> Only 2 studies included more than 10 patients, one reporting a CR in 4 out of 14 patients using a Cisplatin, 5-FU and bleomycin regime<sup>22</sup>, and another reporting a PR rates of 56% and 47% using either platinum or taxane based chemotherapies respectively. Immunotherapy is mostly described using interferon alpha with or without chemotherapy, with the highest CR of 50% when combining Retinoid acid, interferon alpha and Cisplatin.<sup>23-26</sup>

More recently targeted therapies have been used for advanced cSCC.<sup>25, 28-30</sup> Two large studies evaluated the effectiveness of cetuximab and panitumumab in locally advanced- and metastasized cSCC.<sup>28, 30</sup> Maubec *et al.* found a CR of 6%, a PR of 26% and an overall survival 8.1 months with cetuximab, with 47% of the patients having locally advanced cSCC.<sup>28</sup> Foote *et al.* found an OR of 31% with panitumumab, including the 13 patients with locally advanced cSCC.<sup>30</sup>

There is very limited data regarding durable responses of radiotherapy as single treatment in locally advanced cSCC, however adjuvant radiotherapy can significantly improve survival in patients with lymph node metastases.<sup>23</sup>

Although the side effects of the TM-ILPs were low in this cohort, we did observe two (7%) in hospital deaths within 3 months after TM-ILP which is rare for ILP treatment. One of these patients died of pulmonary complications, while this patient was known to have severe

co-morbidity including diabetes and severe COPD. Given the low leakage rate it is unlikely that his postoperative respiratory problems were caused or exacerbated by systemic leakage of the drugs, although we cannot rule this out completely. The second patient died of a complication that was directly attributable to ILP (sepsis subsequent to an infected arterial graft after an rupture of the brachial artery at the site of cannulation). Experience from larger series of ILP for the treatment of sarcoma and melanoma indicate that the mortality rate associated with ILP is less than 1%<sup>15-17, 31-34</sup> Of interest, both patients were classified as American Society of Anesthesiologists physical status classification system (ASA)-3 patients, and both patients were treated in the early stages of this ILP treatment. Both centres are far more experienced with the procedure now than 15 years ago, and patient selection is more strict when it comes to patients with (severe) co-morbidity.

This study is limited by the relatively small number of patients, and therefore the results should be read with caution. Also, outcome could not be assessed in 3 out of 30 patients potentially leading to a bias in response rates. Nevertheless even with these caveats the response rates remain higher than other reported treatments.<sup>21-30</sup>

Of interest, the agents used for ILP are derived from the melanoma ILP protocol. In literature, results of ILP are reported combining doxorubicin with TNF- $\alpha$  showing similar results.<sup>35, 36</sup> These results are promising, and exploration of other chemotherapeutic agents to possibly achieve even higher response rates could be interesting for the future.

In conclusion, TM-ILP is an effective treatment option for patients with locally advanced cSCC based on this study. Altogether, TM-ILP should be considered as an option in locally advanced cSCC patients.

## ***Additional Information***

Conflict of interest: The authors declare no conflict of interest.

Funding: The authors received no funding for this research.

Authorship: All authors contributed to the writing of this article. Mister Hayes and mister van Houdt were the main coordinators of this project. Mister Deroose and Miss Huis in 't Veld conducted the retrospective inclusion of all patients.

Consent for publication: Consent was given for the publications of the Photographs of the patient treated with Isolated Limb Perfusion for advanced extremity cutaneous Squamous Cell Carcinoma.

Ethics approval and consent to participate: The study was conducted according to the Good Clinical Practice guidelines and the Declaration of Helsinki.

Availability of data and materials: All data used for this research is de-identified and stored in SPSS files or Excel spreadsheets.

Acknowledgements: We acknowledge the contribution of our colleagues from all participating hospitals for helping us to collect the data.

## References

1. Diepgen TL, Mahler V. The epidemiology of skin cancer. *Br J Dermatol*. 2002;146 Suppl 61:1-6.
2. Marks R. An overview of skin cancers. Incidence and causation. *Cancer*. 1995;75(2 Suppl):607-12.
3. Gray DT, Suman VJ, Su WP, Clay RP, Harmsen WS, Roenigk RK. Trends in the population-based incidence of squamous cell carcinoma of the skin first diagnosed between 1984 and 1992. *Archives of dermatology*. 1997;133(6):735-40.
4. Staples M, Marks R, Giles G. Trends in the incidence of non-melanocytic skin cancer (NMSC) treated in Australia 1985-1995: are primary prevention programs starting to have an effect? *Int J Cancer*. 1998;78(2):144-8.
5. Trakatelli M, Ulrich C, del Marmol V, Euvrard S, Stockfleth E, Abeni D. Epidemiology of nonmelanoma skin cancer (NMSC) in Europe: accurate and comparable data are needed for effective public health monitoring and interventions. *Br J Dermatol*. 2007;156 Suppl 3:1-7.
6. Holterhues C, Vries E, Louwman MW, Koljenovic S, Nijsten T. Incidence and trends of cutaneous malignancies in the Netherlands, 1989-2005. *J Invest Dermatol*. 2010;130(7):1807-12.
7. Hollestein LM, de Vries E, Nijsten T. Trends of cutaneous squamous cell carcinoma in the Netherlands: increased incidence rates, but stable relative survival and mortality 1989-2008. *European journal of cancer (Oxford, England : 1990)*. 2012;48(13):2046-53.
8. Verkouteren JAC, Ramdas KHR, Wakkee M, Nijsten T. Epidemiology of basal cell carcinoma: scholarly review. *Br J Dermatol*. 2017;177(2):359-72.
9. Kwa RE, Campana K, Moy RL. Biology of cutaneous squamous cell carcinoma. *Journal of the American Academy of Dermatology*. 1992;26(1):1-26.
10. North JH, Jr., Spellman JE, Driscoll D, Velez A, Kraybill WG, Petrelli NJ. Advanced cutaneous squamous cell carcinoma of the trunk and extremity: analysis of prognostic factors. *Journal of surgical oncology*. 1997;64(3):212-7.
11. Lienard D, Ewalenko P, Delmotte JJ, Renard N, Lejeune FJ. High-dose recombinant tumor necrosis factor alpha in combination with interferon gamma and melphalan in isolation perfusion of the limbs for melanoma and sarcoma. *Journal of clinical oncology : official journal of the American Society of Clinical Oncology*. 1992;10(1):52-60.
12. Eggermont AM, de Wilt JH, ten Hagen TL. Current uses of isolated limb perfusion in the clinic and a model system for new strategies. *The Lancet Oncology*. 2003;4(7):429-37.
13. Deroose JP, Grunhagen DJ, van Geel AN, de Wilt JH, Eggermont AM, Verhoef C. Long-term outcome of isolated limb perfusion with tumour necrosis factor-alpha for patients with melanoma in-transit metastases. *The British journal of surgery*. 2011.
14. Grunhagen DJ, de Wilt JH, Graveland WJ, Verhoef C, van Geel AN, Eggermont AM. Outcome and prognostic factor analysis of 217 consecutive isolated limb perfusions with tumor necrosis factor-alpha and melphalan for limb-threatening soft tissue sarcoma. *Cancer*. 2006;106(8):1776-84.
15. Smith HG, Cartwright J, Wilkinson MJ, Strauss DC, Thomas JM, Hayes AJ. Isolated Limb Perfusion with Melphalan and Tumour Necrosis Factor alpha for In-Transit Melanoma and Soft Tissue Sarcoma. *Annals of surgical oncology*. 2015;22 Suppl 3:S356-61.
16. Vrouwenraets BC, Eggermont AM, Hart AA, Klaase JM, van Geel AN, Nieweg OE, et al. Regional toxicity after isolated limb perfusion with melphalan and tumour necrosis factor-alpha versus toxicity after melphalan alone. *European journal of surgical oncology : the journal of the European Society of Surgical Oncology and the British Association of Surgical Oncology*. 2001;27(4):390-5.

17. Eggermont AM, Schraffordt Koops H, Klausner JM, Kroon BB, Schlag PM, Lienard D, et al. Isolated limb perfusion with tumor necrosis factor and melphalan for limb salvage in 186 patients with locally advanced soft tissue extremity sarcomas. The cumulative multicenter European experience. *Ann Surg.* 1996;224(6):756-64; discussion 64-5.
18. Wieberdink J, Benckhuysen C, Braat RP, van Slooten EA, Olthuis GA. Dosimetry in isolation perfusion of the limbs by assessment of perfused tissue volume and grading of toxic tissue reactions. *Eur J Cancer Clin Oncol.* 1982;18(10):905-10.
19. WHO. Handbook for reporting results of cancer treatment. Geneva: World Health Organisation; 1979.
20. Olieman AF, Lienard D, Eggermont AM, Kroon BB, Lejeune FJ, Hoekstra HJ, et al. Hyperthermic isolated limb perfusion with tumor necrosis factor alpha, interferon gamma, and melphalan for locally advanced nonmelanoma skin tumors of the extremities: a multicenter study. *Arch Surg.* 1999;134(3):303-7.
21. Jarkowski A, 3rd, Hare R, Loud P, Skitzki JJ, Kane JM, 3rd, May KS, et al. Systemic Therapy in Advanced Cutaneous Squamous Cell Carcinoma (CSCC): The Roswell Park Experience and a Review of the Literature. *American journal of clinical oncology.* 2016;39(6):545-8.
22. Sadek H, Azli N, Wendling JL, Cvitkovic E, Rahal M, Mamelie G, et al. Treatment of advanced squamous cell carcinoma of the skin with cisplatin, 5-fluorouracil, and bleomycin. *Cancer.* 1990;66(8):1692-6.
23. Bejar C, Maubec E. Therapy of advanced squamous cell carcinoma of the skin. *Curr Treat Options Oncol.* 2014;15(2):302-20.
24. Behshad R, Garcia-Zuazaga J, Bordeaux JS. Systemic treatment of locally advanced nonmetastatic cutaneous squamous cell carcinoma: a review of the literature. *Br J Dermatol.* 2011;165(6):1169-77.
25. Ribero S, Stucci LS, Daniels GA, Borradori L. Drug therapy of advanced cutaneous squamous cell carcinoma: is there any evidence? *Current opinion in oncology.* 2017;29(2):129-35.
26. Shin DM, Glisson BS, Khuri FR, Clifford JL, Clayman G, Benner SE, et al. Phase II and biologic study of interferon alfa, retinoic acid, and cisplatin in advanced squamous skin cancer. *Journal of clinical oncology : official journal of the American Society of Clinical Oncology.* 2002;20(2):364-70.
27. Anasagasti-Angulo L, Garcia-Vega Y, Barcelona-Perez S, Lopez-Saura P, Bello-Rivero I. Treatment of advanced, recurrent, resistant to previous treatments basal and squamous cell skin carcinomas with a synergistic formulation of interferons. Open, prospective study. *BMC Cancer.* 2009;9:262.
28. Maubec E, Petrow P, Scheer-Senarich I, Duvillard P, Lacroix L, Gelly J, et al. Phase II study of cetuximab as first-line single-drug therapy in patients with unresectable squamous cell carcinoma of the skin. *Journal of clinical oncology : official journal of the American Society of Clinical Oncology.* 2011;29(25):3419-26.
29. Della Vittoria Scarpati G, Perri F, Pisconti S, Costa G, Ricciardiello F, Del Prete S, et al. Concomitant cetuximab and radiation therapy: A possible promising strategy for locally advanced inoperable non-melanoma skin carcinomas. *Mol Clin Oncol.* 2016;4(4):467-71.
30. Foote MC, McGrath M, Guminski A, Hughes BG, Meakin J, Thomson D, et al. Phase II study of single-agent panitumumab in patients with incurable cutaneous squamous cell carcinoma. *Ann Oncol.* 2014;25(10):2047-52.
31. Deroose JP, Eggermont AM, van Geel AN, Burger JW, den Bakker MA, de Wilt JH, et al. Long-term results of tumor necrosis factor alpha- and melphalan-based isolated limb perfusion in locally advanced extremity soft tissue sarcomas. *Journal of clinical oncology : official journal of the American Society of Clinical Oncology.* 2011;29(30):4036-44.

32. Deroose JP, Eggermont AM, van Geel AN, de Wilt JH, Burger JW, Verhoef C. 20 years experience of TNF-based isolated limb perfusion for in-transit melanoma metastases: TNF dose matters. *Annals of surgical oncology*. 2012;19(2):627-35.
33. Hoven-Gondrie ML, Bastiaannet E, van Ginkel RJ, Suurmeijer AJ, Hoekstra HJ. TNF dose reduction and shortening of duration of isolated limb perfusion for locally advanced soft tissue sarcoma of the extremities is safe and effective in terms of long-term patient outcome. *Journal of surgical oncology*. 2011;103(7):648-55.
34. van Etten B, van Geel AN, de Wilt JH, Eggermont AM. Fifty tumor necrosis factor-based isolated limb perfusions for limb salvage in patients older than 75 years with limb-threatening soft tissue sarcomas and other extremity tumors. *Annals of surgical oncology*. 2003;10(1):32-7.
35. Rastrelli M, Campana LG, Valpione S, Tropea S, Zanon A, Rossi CR. Hyperthermic isolated limb perfusion in locally advanced limb soft tissue sarcoma: A 24-year single-centre experience. *International journal of hyperthermia : the official journal of European Society for Hyperthermic Oncology, North American Hyperthermia Group*. 2016;32(2):165-72.
36. Di Filippo F, Giacomini P, Rossi CR, Santinami M, Garinei R, Anza M, et al. Hyperthermic isolated perfusion with tumor necrosis factor-alpha and doxorubicin for the treatment of limb-threatening soft tissue sarcoma: the experience of the Italian Society of Integrated Locoregional Treatment in Oncology (SITILO). *In vivo (Athens, Greece)*. 2009;23(2):363-7.

## Tables and figures

**Table 1. Patients, tumor and treatment characteristics**

	N (%)	Median (range)
<b>Gender</b>		
Male	15 (50)	
Female	15 (50)	
<b>Age</b>		
In years		71 (36-92)
<b>Size*</b>		
≤5cm	10 (38)	
>5cm	16 (62)	
<b>Site</b>		
Arm	3 (10)	
Hand or wrist	5 (17)	
Leg	16 (53)	
Ankle or foot	7 (20)	
<b>Number of tumors</b>		
Unifocal	24 (80)	
Multifocal	6 (20)	
<b>Disease stage cSCC at presentation</b>		
Primary	18 (60)	
Recurrent	10 (33)	
Metastatic	2 (7)	
<b>Concurrent metastasis</b>		
None	25 (83)	
Lymph node	3 (10)	
Distant	2 (7)	
<b>Surgical approach</b>		
Axillary	3 (10)	
Brachial	6 (20)	
Femoral	20 (67)	
Iliac	1 (3)	
<b>Doses</b>		
TNF** (mg)		2 (1-3)
Melphalan** (mg)		60 (25-80)
<b>Hospital stay</b>		
In days		6 (1-72)

\* unknown size (n=4) \*\* median dose in mg; cSCC = cutaneous squamous cell carcinoma; TM-ILP = TNF and melphalan based isolated limb perfusion

**Table 2. Patient characteristics per response to ILP**

	CR* (n, %)	PR** (n, %)	PD*** (n, %)	P-value
<b>Size</b>				
<5cm	6 (43)	2 (50)	2 (40)	1.000 <sup>F</sup>
>5cm	8 (57)	2 (50)	3 (60)	
<b>Number of tumors</b>				
Unifocal	13 (81)	5 (83)	3 (60)	0.246 <sup>F</sup>
Multifocal	3 (19)	1 (17)	2 (40)	
<b>Disease stage cSCC**** at presentation</b>				
Primary	10 (63)	4 (67)	2 (40)	0.248 <sup>F</sup>
Recurrence	2 (12)	1 (17)	1 (20)	
Multiple recurrence	4 (25)	1 (17)	2 (40)	
<b>Location</b>				
Arm	2 (13)	0 (0)	1 (20)	0.263 <sup>F</sup>
Wrist or hand	2 (13)	2 (33)	0 (0)	
Leg	7 (44)	3 (50)	4 (80)	
Foot or ankle	5 (31)	1 (17)	0 (0)	

\*CR=Complete response, \*\*PR=Partial response, \*\*\*PD=progressive disease, \*\*\*\* cSCC=cutaneous Squamouscellcarcinoma, F=Fisher exact test



**Table 3. Response, local recurrence and systematic disease**

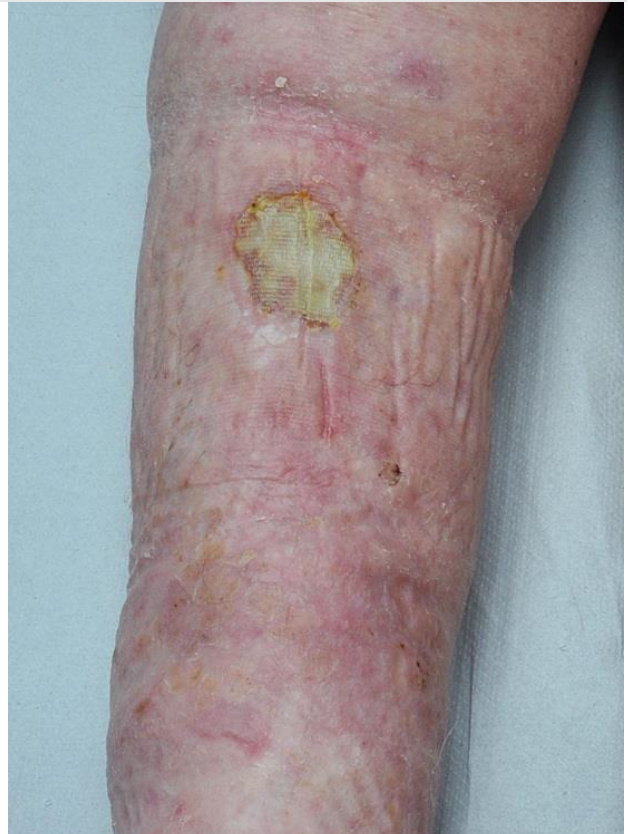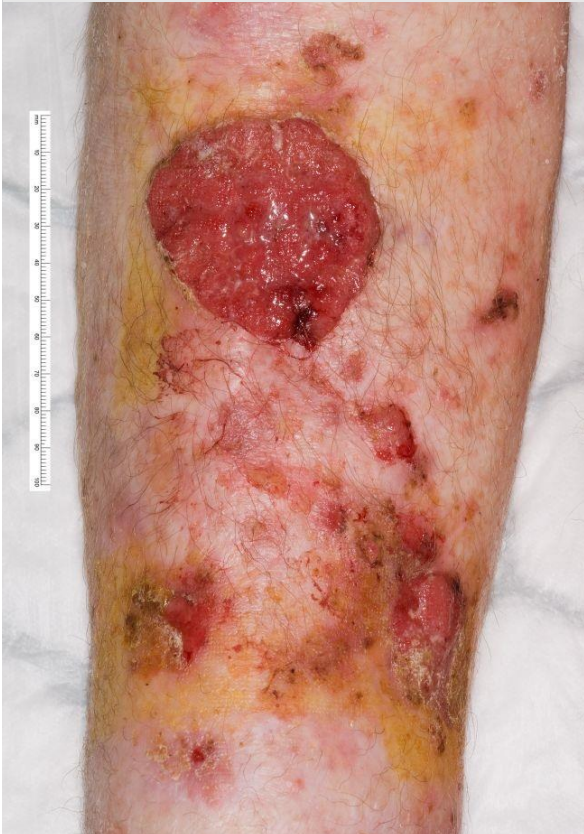Type of response*	Patients (n,%)	Local progression (n, %)	Months to local progression (median, range)	metastatic disease** (n,%)	Months to metastatic disease (median, range)
Complete response	16 (59)	4 (25)	9 (9-22)	4*** (25)	0 (0-21)
Partial response	6 (22)	3 (50)	4 (2-6)	3 (33)	3 (3-9)
Progressive disease	5 (19)	N/A	0 (0-0)	3**** (60)	0 (0-4)
Overall response	22 (81)	7 (23)	9 (2-22)	10 (32)	3 (0-21)

\*for 3 patients response could not be assessed, \*\* metastatic disease includes regional and distant metastasis. \*\*\* 3 patients already had metastatic disease at time of ILP, \*\*\*\* 2 patients already had metastatic disease at time of ILP

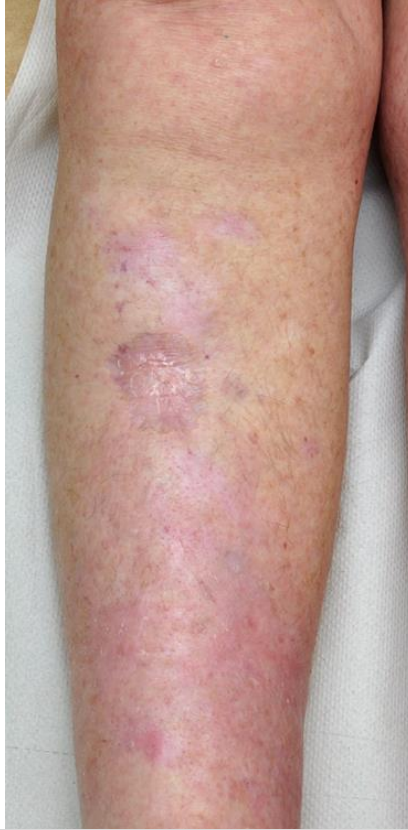**Figure 1: Course of a complete response of the lower leg**

Pre-ILP TM-ILP

Two months after TM-ILP

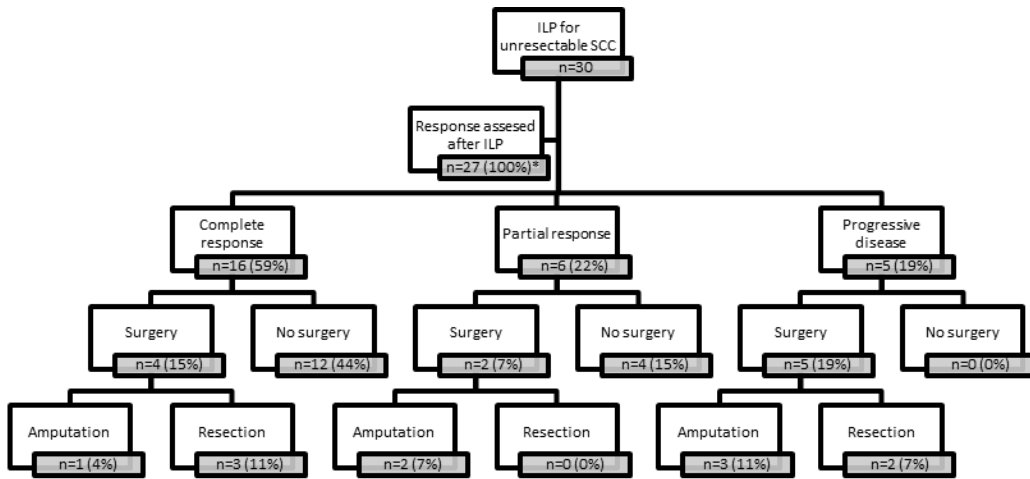


Ongoing response 9 months after TM-ILP



TM-ILP = TNF and melphalan based isolated limb perfusion

**Figure 2: Consort diagram of patients per response group and surgical intervention**



\* in three patients response could not be evaluated