

Diffusion-weighted MRI for detecting prostate tumour in men at increased genetic risk

Nandita M. deSouza^{a,*}, Veronica A. Morgan^a, Elizabeth Bancroft^b, S. Aslam Sohaib^c, Sharon L. Giles^a, Zsofia Kote-Jarai^b, Elena Castro^b, Steven Hazell^d, Maysam Jafar^a, Rosalind Eeles^b

^a CRUK and EPSRC Cancer Imaging Centre, Institute of Cancer Research and Royal Marsden NHS Foundation Trust, Downs Road, Surrey SM2 5PT, UK

^b Genetics and Epidemiology, Institute of Cancer Research and Royal Marsden NHS Foundation Trust, Downs Road, Surrey SM2 5PT, UK

^c Department of Radiology, Royal Marsden NHS Foundation Trust, Downs Road, Surrey SM2 5PT, UK

^d Department of Histopathology, Royal Marsden NHS Foundation Trust, Downs Road, Surrey SM2 5PT, UK

Received 21 August 2014; accepted 24 August 2014

Available online 7 September 2014

Abstract

Background: Diffusion-weighted (DW)-MRI is invaluable in detecting prostate cancer. We determined its sensitivity and specificity and established interobserver agreement for detecting tumour in men with a family history of prostate cancer stratified by genetic risk.

Methods: 51 men with a family history of prostate cancer underwent T2-W + DW-endorectal MRI at 3.0 T. Presence of tumour was noted at right and left apex, mid and basal prostate sextants by 2 independent observers, 1 experienced and the other inexperienced in endorectal MRI. Sensitivity and specificity against a 10-core sampling technique (lateral and medial cores at each level considered together) in men with >2× population risk based on 71 SNP analysis versus those with lower genetic risk scores was established. Interobserver agreement was determined at a subject level.

Results: Biopsies indicated cancer in 28 sextants in 13/51 men; 32 of 51 men had twice the population risk (>0.25) based on 71 SNP profiling. Sensitivity/specificity per-subject for patients was 90.0%/86.4% (high-risk) vs. 66.7%/100% (low-risk, observer 1) and 60.0%/86.3% (high-risk) vs. 33.3%/93.8% (low-risk, observer 2) with moderate overall inter-observer agreement ($\kappa = 0.42$). Regional sensitivities/specificities for high-risk vs. low-risk for observer 1 apex 72.2%/100% [33.3%/100%], mid 100%/93.1% [100%/97.3%], base 16.7%/98.3% [0%/100%] and for observer 2 apex 36.4%/98.1% [0%/100%], mid 28.6%/96.5% [100%/100%], base 20%/100% [0%/97.3%] were poorer as they failed to detect multiple lesions.

Conclusion: Endorectal T2W + DW-MRI at 3.0 T yields high sensitivity and specificity for tumour detection by an experienced observer in screening men with a family history of prostate cancer and increased genetic risk.

© 2014 The Authors. Published by Elsevier Ltd. This is an open access article under the CC BY-NC-ND license (<http://creativecommons.org/licenses/by-nc-nd/3.0/>).

Keywords: Prostate cancer; MRI; Diffusion-weighted; Genetic risk; Screening; Detection

Abbreviations: ADC, apparent diffusion coefficient; DW, diffusion-weighted; FoV, field of view; HIPAA, Health Insurance Portability and Accountability Act; iCOGS, Illumina Collaborative Oncological Gene-Environment Study; MRI, magnetic resonance imaging; PSA, prostate specific antigen; SNP, single nucleotide polymorphism; STARD, Standards for the Reporting of Diagnostic Accuracy Studies; TR, repetition time; TE, time to echo; TRUS, transrectal ultrasound.

* Corresponding author at: CRUK/EPSRC Imaging Centre, MRI Unit, Institute of Cancer Research and Royal Marsden NHS Foundation Trust, Downs Road, Surrey SM2 5PT, UK. Tel.: +44 20 8661 3119/3289; fax: +44 20 8661 0846.

E-mail address: nandita.deSouza@icr.ac.uk (N.M. deSouza).

1. Introduction

Men with a strong family history of prostate cancer (defined as a first degree relative with histologically or death certificate proven prostate cancer diagnosed at <70 years or 2 relatives on the same side of the family where at least one is diagnosed at <70 years or ≥ 3 relatives on the same side of the family diagnosed at any age) carry an increased risk of the disease compared to the general population [1,2]. Seventy-six single nucleotide polymorphisms have been shown to be significantly associated with

prostate cancer in these men [3,4]. The detection of prostate cancer in this population however, remains reliant on random, non-targetted multiple biopsies of the gland, which are painful and carry a significant morbidity whilst not necessarily sampling a relevant lesion. Diffusion-weighted MRI, when used in conjunction with T2-W MRI has been shown to be sensitive at detecting clinically significant prostate cancers [5] especially when random sampling in men with raised prostate specific antigen (PSA) is initially negative [6]. Moreover, the quantified apparent diffusion coefficient (ADC), which reflects the water diffusivity in the extracellular space, is increasingly restricted as tumours increase in cellularity [7] so that ADC correlates with Gleason grade [8,9] and is invaluable in detecting significant cancers. DW-MRI is easy to implement as a standard technique on current MRI platforms, and an ADC map derived using scanner software can be visually assessed for the presence of tumour as an area of restricted diffusion, as well as being quantifiable. The purpose of this study therefore was to determine the sensitivity and specificity of T2W + DW-MRI as a screening tool in men with a family history of prostate cancer stratified by genetic risk and establish interobserver agreement for detecting tumour.

2. Methods

2.1. Subjects

This pilot diagnostic accuracy study had Institutional Review Board approval and was performed as a single institution study at a National Cancer Centre. Ethical standards complied with the Helsinki Declaration of 1975 as revised in 2013. Between January 2010 and July 2012, men aged 41–68 years (mean 53.4 ± 8.5 years) with a positive family history of prostate cancer defined as (i) one first degree relative with histology or death-certificate proven prostate cancer at <70 years, (ii) 2 relatives on the same side of the family with prostate cancer where one is diagnosed at <70 years or (iii) ≥ 3 relatives on the same side of the family of any age, were invited into the study. Those with a previous cancer and with a terminal prognosis of <5 years or with a previous diagnosis of prostate cancer but with a current negative biopsy were excluded. Fifty-four patients were approached to undergo MRI within this study: 2 declined because of claustrophobia, the third had a high body mass index and had previously experienced discomfort being positioned in an MRI scanner, so declined. Fifty-one consecutive men willing to undergo endorectal MRI followed by a 10-core transrectal ultrasound guided biopsy therefore were prospectively recruited. All subjects were imaged following written informed consent. PSA was 1.9 ± 1.7 ng/mL (mean \pm standard deviation). The median interval between imaging and subsequent biopsy was 15 days (lower quartile 6.5 days, upper quartile 29 days). Although limited by the non-targetted approach to biopsy, transrectal ultrasound guided random sampling of the prostate remains the gold-standard for prostate cancer diagnosis.

2.2. SNP analysis and scores

The participant's DNA was genotyped on the iCOGS (Illumina, Collaborative Oncological Gene-Environment Study) chip. iCOGS is a custom Illumina iSelect genotyping array, designed to test genetic variants related to three hormone related cancers of which prostate cancer is one [3]. Data was available for 71 of the 76 previously identified known prostate cancer susceptibility SNPs; 61 were directly genotyped and for 10 loci we used data for a proxy SNP with a linkage disequilibrium >0.75 (3). The cumulative SNP risk score for each patient was calculated by summing 71 risk alleles using the weighted effect (log-additive model) as estimated in previous studies [10]. Patients were divided into those having a low risk (score <0.25) or high risk (score ≥ 0.25), where 0.25 represented twice the lifetime risk of 1 in 8 (0.125) in a normal population [11].

2.3. Imaging methods

Images were acquired on a 3 T Philips Achieva (Best, Netherlands) using an endorectal coil (Medrad Inc., PA, USA) in combination with an external phased array coil. The endorectal balloon was inflated with 60 ml of perfluorocarbon. Hyoscine butyl bromide was administered routinely as an antiperistaltic agent. T2-W images were obtained in 3 planes orthogonal to the prostate (FSE, TR 2500 ms, TE 110 ms, FoV 14 cm, slice thickness 2.2 mm, matrix 220×184 extrapolated to 256×256) and were complemented by diffusion weighted images in the transverse plane (single shot EPI, TR 5243 ms, TE 72 ms, $b=0, 100, 800$ s/mm², FOV 180 mm, slice thickness 2.2 mm, matrix $80 \text{ m} \times 71 \text{ m}$, extrapolated to 128×128). Whole pelvis imaging was not deemed to be a requirement in this cohort.

2.4. Biopsy procedure and histology analysis

Ten cores were obtained using a random sampling technique (lateral and medial gland base, lateral and medial mid gland and apex from right and left lobes) under transrectal ultrasound (TRUS) guidance. The systematic biopsies were not formally registered to the MR data, although the MR images and reports were available to the operator performing the biopsies, so that visual account could be taken of the position of any identified lesions. Routine antibiotic prophylaxis was administered with Ciprofloxacin 500 mg twice daily and intrarectal Metronidazole 1 g capsule 1–2 h prior to the procedure.

Sections obtained using 18-G Tru-cut needles were stained with haematoxylin and eosin and the presence or absence of cancer and its Gleason grading were noted by a specialist uropathologist. For the purposes of comparison with imaging the lateral and medial cores at the base and mid gland of each side were scored together as either positive or negative for tumour.

2.5. Data analysis

Apparent diffusion coefficient (ADC) maps were derived for every voxel in the image using all b -values and a monoexponential fit of the data. Images were assessed by 2 observers; the

first had a considerable experience of endorectal imaging and of reporting prostate imaging in a population managed by active surveillance, the second was a dedicated urologist without experience of endorectal MRI and did not have experience of regular reporting a low-risk (Gleason 3 + 3) prostate cancer population. The differences in observer performance were deliberately addressed in order to understand how this technique might perform outside very specialist hands. The T2-W images, diffusion-weighted images and ADC maps were viewed together and each sextant (superior third = basal, middle third = mid and inferior third = apex for right and left sides) scored as positive or negative for tumour by each observer independently. Tumour was defined as a focal area of low signal-intensity within the peripheral zone of the prostate that corresponded to an area of restricted diffusion on the ADC map; in the central gland of the prostate criteria included homogeneity of the focal low signal-intensity lesion with mass effect in order to exclude stromal nodules of benign prostatic hyperplasia. Sensitivity and specificity for identifying tumour within the prostate on a per-subject as well as on a per-sextant basis was determined for each observer. A kappa statistic was used to determine interobserver agreement.

All statistical tests used a value of less than 5% to denote significance.

3. Results

No adverse events were experienced by any subject as a result of endorectal MRI. Following biopsy, twenty eight sextants in 13/51 men were positive for tumour (1 sextant in 5 men, 2 in 5 men, 3 in 1 man, 4 in 1 man and 6 in 1 man). All lesions were Gleason 3 + 3; percentage of tumour length to total core length ranged from 0.4% to 10% (median 1.6%). 32 of 51 patients had cumulative risk scores of >0.25 based on 71 SNPs. As biopsy was performed after MRI in all cases, there was no artefact from haemorrhage on imaging.

3.1. Per-subject analysis

On MRI, lesions were sited in the peripheral zone in all but 1 case where it was located across both peripheral zone and central gland. In the high-risk group, the incidence of positive biopsy was 31.3% (10 of 32 cases), of which MRI detected 9 cases by observer 1 and 6 cases by observer 2. In the low-risk group, the incidence of positive biopsy was 15.8% (3 of 19 cases), of which MRI detected 2 cases by observer 1 and 1 case by observer 2. Sensitivity and specificity for each observer by group are given in Table 1, and the Standards for the Reporting of Diagnostic Accuracy Studies (STARD) flow chart is given in Fig. 1. For the whole cohort at a per-subject level, agreement between observers was moderate (kappa = 0.42).

3.2. Per-sextant analysis

In the high-risk group 23 of 192 sextants were positive on histology (12%) of which 15 were detected by observer 1 and 7 by observer 2. In the low-risk group 5 sextants of 114 (4.4%) were

Table 1

Sensitivity, specificity, by 2 independent observers for identifying tumour within the prostate in a screening population at high risk.

		Observer 1 risk score		Observer 2 risk score	
		>0.25	<0.25	>0.25	<0.25
Whole prostate	Sens%	90.0	66.7	60	33.3
	Spec%	86.4	100	86.3	93.8
	PPV%	75.0	100	66.7	50.0
	NPV%	95.0	94.1	82.6	88.2
Apex	Sens %	72.7	33.3	36.4	0
	Sens%	100	100	98.1	100
	Spec%	100	100	80.0	0
	PPV%	94.6	94.6	88.1	92.1
Mid	Sens%	100	100	28.6	100
	Spec%	93.1	100	96.5	100
	PPV%	60.0	100	50.0	100
	NPV%	100	100	91.7	100
Base	Sens%	16.7	0	16.7	0
	Spec%	98.3	100	100	97.3
	PPV%	50.0	0	100	0
	NPV%	91.9	97.4	92.1	97.3

positive on histology of which 2 were detected by observer 1 and 1 by observer 2. Sensitivity and specificity for each observer on a regional (apex, mid, base) basis is given in Table 1. For the 8 men with 2 or more sextants positive, observer 1 identified multiple abnormal sextants in 5 cases, while observer 2 identified multiple abnormal sextants in 1 case only. A true positive case is illustrated in Fig. 2 and a false positive case in Fig. 3.

4. Discussion

This study has indicated that TRUS random sampling biopsy picked up prostate cancer in 31% of men with a family history of the disease stratified as high-risk (risk twice that of normal population) based on 71 SNP analysis and that DW-MRI by an experienced observer identified 90% of these with a 86% specificity. This is in keeping with previous data from an active surveillance population where similar levels of sensitivity and specificity were recorded in a population all of whom had previous positive biopsies [12]. As with the active surveillance population, the sensitivity achieved is likely related to lesion size and Gleason grade as many of these cancers are of small size and low Gleason grade. The sensitivity of ADC as a biomarker has been linked to Gleason grade [9] and ADC has been shown to be significantly lower in aggressive disease [13]. Also the spatial resolution of the technique used in this study, with a pixel size of ~6 mm² meant that lesions of <3 contiguous pixels of low ADC (18 mm²) were unlikely to be recognised as tumour.

The difference in sensitivity and specificity between observers is also in line with previous data where lower sensitivity and specificity was observed with observers inexperienced in low risk disease such as in an active surveillance population [12]. These data are in keeping with that from other studies, where sensitivities and specificities improved from 54% to 81% with minimal loss of specificity (91–84% respectively) for Gleason 3 + 3 lesions of ~4 mm by an experienced observer when

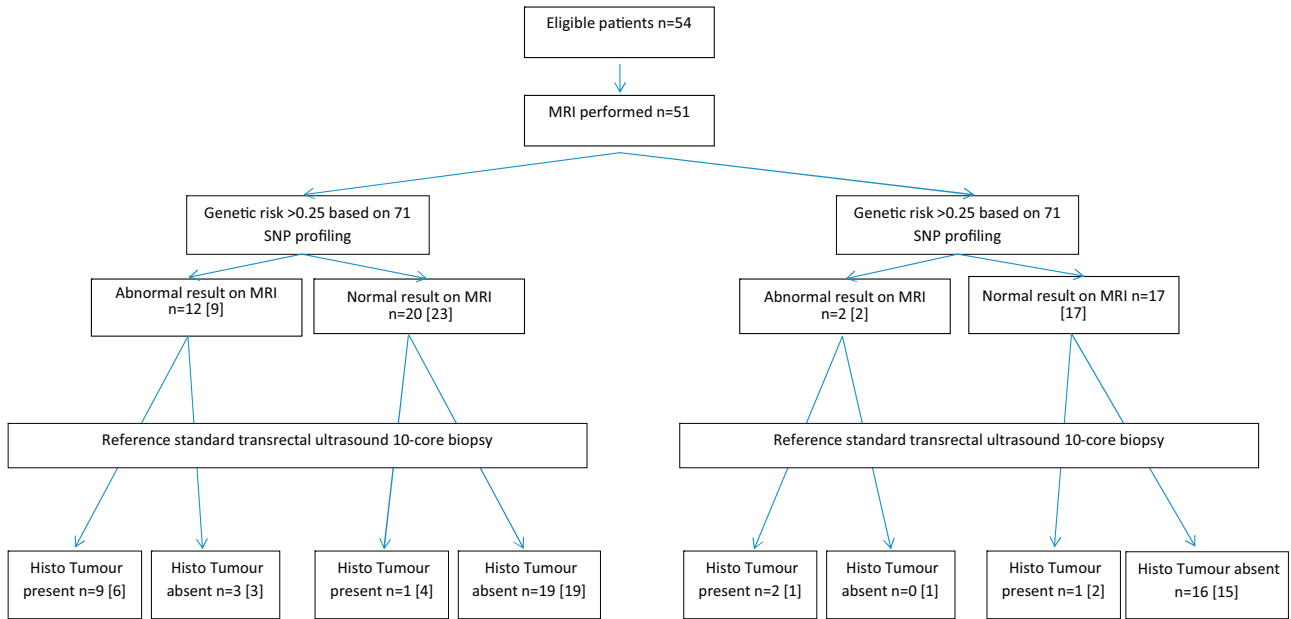


Fig. 1. STARD flow chart for index test (endorectal diffusion-weighted MRI at 3.0 T) for detecting tumour by observer 1 and observer 2 against a standard 10-core random sampling transrectal ultrasound biopsy technique in men with a family history of prostate cancer stratified by genetic risk.

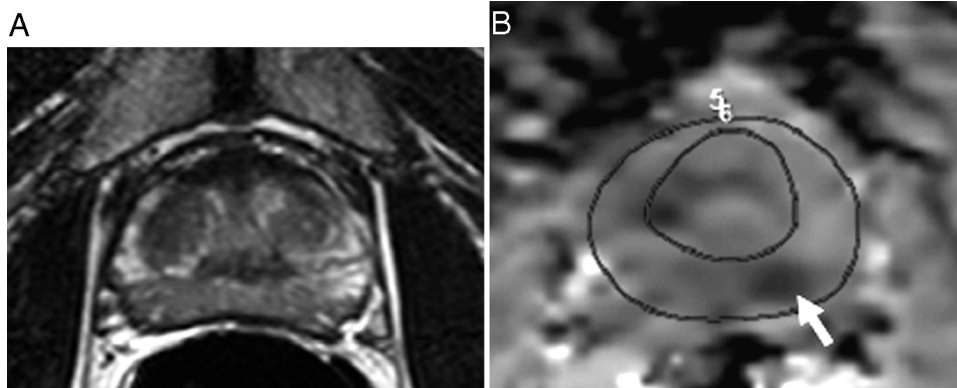


Fig. 2. True positive for prostate cancer in a 58 year old man: transverse T2-W images (FSE 2500/80 ms [TR/TE]) images (A) through the mid prostate obtained with an endorectal coil at 3.0 T and corresponding ADC maps (B) generated from a monoexponential fit of diffusion-weighted data (EPI 8000/69 ms [TR/TE], $b=0, 100, 800 \text{ mm}^2/\text{s}$). Outlines for whole prostate and central gland are given on the ADC maps. A lesion is not visible on the T2-W images, but a focally restricted area on the ADC maps (arrow) corresponded to a positive biopsy from that sextant.

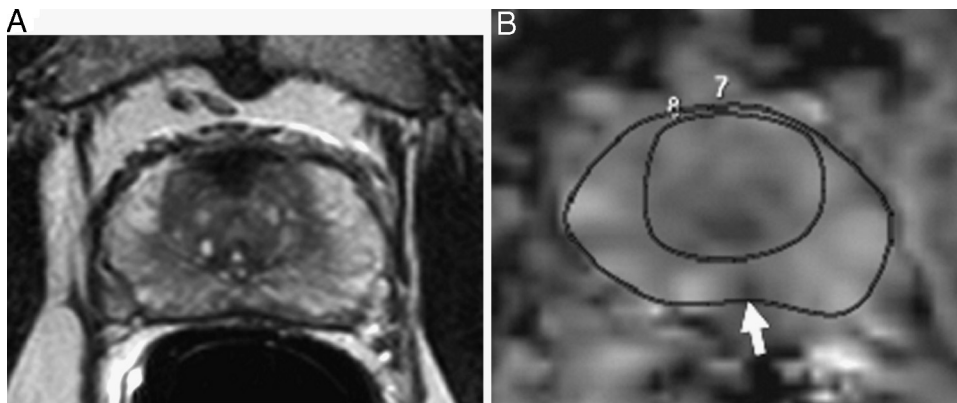


Fig. 3. False positive for prostate cancer in a 46 year old man: transverse T2-W images (FSE 2500/80 ms [TR/TE]) images (A) through the mid prostate obtained with an endorectal coil at 3.0 T and corresponding ADC maps (B) generated from a monoexponential fit of diffusion-weighted data (EPI 8000/69 ms [TR/TE], $b=0, 100, 800 \text{ mm}^2/\text{s}$). Outlines for whole prostate and central gland are given on the ADC maps. Although a lesion is not visible on the T2-W image, a small focally restricted area on the ADC maps (arrow) was seen medially. However, all 12 biopsies from this subject were negative for tumour.

DWI was added to the T2W imaging [14]. Other multiobserver studies have similarly recorded a wide range in sensitivity and specificity: in a multireader ($n=6$) study, variation in these parameters ranged from 26 to 51% and 47 to 72% respectively [15]. Although the reason for these variations has not been interrogated, it is likely to relate to lesion size and the fact that subtle variations in ADC with lower Gleason grade tumours adversely influence interpretation.

The sensitivity and specificity for detecting tumour at a sextant level were poorer. Two factors are likely to have contributed to this: firstly in patients with multiple tumours, MRI only identified one or some of the lesions. In 6 patients with multiple lesions, not all the lesions were identified on imaging. It is also possible that these were part of the same tumour, and so contiguous on MRI, whereas histology identified them on 2 separate cores. It is possible that a multiparametric approach, for example the inclusion of DCE MRI may have improved this [16], but the increased complexity in scan time, analysis time and cost is not warranted in a screening setting. Secondly, definitions of apex, mid and base are arbitrary and while we divided the gland visually into “thirds” on MRI, this level of discrimination would not have been possible during transrectal biopsy sampling making registration between adjacent sextants on MRI and histology imperfect. Finally, the contrast between tumour and normal tissue at the base of the prostate is reduced by the MR appearances of the normal central zone, which classically has a much shorter T2 relaxation than the normal peripheral zone. This is due to its unique histology comprising crowded tall columnar cells associated with thick muscle bundles at the bladder neck [17]. This may explain the lower sensitivity for recognizing tumour at the gland base.

This pilot study has some limitations. Most importantly, the presence of cancer was based on 10 core TRUS biopsy which uses a random sampling technique. Our negative cases may therefore not have been truly negative had a more aggressive sampling scheme such as template biopsy been considered. Template biopsies in healthy men in a screening context are poorly acceptable to patients. They often necessitate a general anaesthetic and carry a significant morbidity, which is difficult to justify in a screening population. In the first instance, therefore we undertook a pilot study with TRUS biopsy to determine whether we were able to pick up anything before a formal study that incorporated template biopsy. Secondly, the diffusion-weighted techniques employed although they used an endorectal technique at 3 T, could be improved by newer reduced field of view techniques such as zonal oblique multislice imaging [18] which allow much greater spatial resolution without significant reduction in signal to noise ratio or increased acquisition time. In a screening population where safety of the diagnostic intervention is paramount, use of a technique that does not involve ionizing radiation or administration of a contrast agent is ideal. At a very minimum 4 sequences would be required, bringing scan time down to 20 min; it is likely that future improvements in scanner hardware and software reduce this further. However, cost–benefit is also an issue and MRI although now widely available incurs a significant financial burden. The restriction of its use to those genetically stratified as being at high-risk or by a

combination of PSA and genetic risk will be of major importance in implementing this technique in a screening population. In the first instance, establishing the robustness and accuracy in a larger multicentre trial is warranted.

In summary, we have shown in a pilot study that T2W + DW-MRI is able to detect 90% of men with prostate cancer in a screening population with a family history of the disease and a $>2\times$ population risk based on genetic profiling, but that experienced observer interpretation is required. Improvements in the process of automated analysis would advance this technique in a larger population study, which are currently in the process of setting up.

Funding

The Imaging Centre is supported by CRUK and EPSRC in association with MRC and Department of Health C1060/A10334. We gratefully acknowledge NIHR support to the Clinical Research Facility in Imaging and funding to the NIHR Biomedical Research Centre at The Institute of Cancer Research and The Royal Marsden NHS Foundation Trust. RE is supported by CRUK 5047/A15007.

Conflicts of interest

The authors have no conflicts of interest to declare with regard to the subject matter of this research.

Acknowledgements

We thank Natalie Taylor and Lucia D’Mello, research nurses for their assistance with the studies.

References

- [1] Kote-Jarai Z, Leongamornlert D, Saunders E, Tymrakiewicz M, Castro E, Mahmud N, et al. BRCA2 is a moderate penetrance gene contributing to young-onset prostate cancer: implications for genetic testing in prostate cancer patients. *Br J Cancer* 2011;105:1230–4.
- [2] Madersbacher S, Alcaraz A, Emberton M, Hammerer P, Ponzolzer A, Schröder FH, et al. The influence of family history on prostate cancer risk: implications for clinical management. *BJU Int* 2011;107:716–21.
- [3] Eeles RA, Olama AA, Benlloch S, Saunders EJ, Leongamornlert DA, Tymrakiewicz M, et al. Identification of 23 new prostate cancer susceptibility loci using the iCOGS custom genotyping array. *Nat Genet* 2013;45:385–91.
- [4] Goh CL, Saunders EJ, Leongamornlert DA, Tymrakiewicz M, Thomas K, Selvadurai ED, et al. Clinical implications of family history of prostate cancer and genetic risk single nucleotide polymorphism (SNP) profiles in an active surveillance cohort. *BJU Int* 2013;112:666–73.
- [5] Thoeny HC, Forstner R, De Keyzer F. Genitourinary applications of diffusion-weighted MR imaging in the pelvis. *Radiology* 2012;263:326–42.
- [6] Park BK, Lee HM, Kim CK, Choi HY, Park JW. Lesion localization in patients with a previous negative transrectal ultrasound biopsy and persistently elevated prostate specific antigen level using diffusion-weighted imaging at three Tesla before rebiopsy. *Investig Radiol* 2008;43:789–93.
- [7] Gibbs P, Liney GP, Pickles MD, Zelhof B, Rodrigues G, Turnbull LW. Correlation of ADC and T2 measurements with cell density in prostate cancer at 3.0 Tesla. *Investig Radiol* 2009;44:572–6.
- [8] Kitajima K, Takahashi S, Ueno Y, Miyake H, Fujisawa M, Kawakami F, et al. Do apparent diffusion coefficient (ADC) values obtained using high

- b-values with a 3-T MRI correlate better than a transrectal ultrasound (TRUS)-guided biopsy with true Gleason scores obtained from radical prostatectomy specimens for patients with prostate cancer. *Eur J Radiol* 2013;82:1219–26.
- [9] Nagarajan R, Margolis D, Raman S, Sarma MK, Sheng K, King CR, et al. MR spectroscopic imaging and diffusion-weighted imaging of prostate cancer with Gleason scores. *J Magn Resonan Imaging* 2012;36:697–703.
- [10] Macinnis RJ, Antoniou AC, Eeles RA, Severi G, Al Olama AA, McGuffog L, et al. A risk prediction algorithm based on family history and common genetic variants: application to prostate cancer with potential clinical impact. *Genet Epidemiol* 2011;35:549–56.
- [11] <http://www.cancerresearchuk.org/cancer-info/cancerstats/incidence/risk/statistics-on-the-risk-of-developing-cancer#Lifetime5>.
- [12] Morgan VA, Kyriazi S, Ashley SE, deSouza NM. Evaluation of the potential of diffusion-weighted imaging in prostate cancer detection. *Acta Radiol* 2007;48:695–703.
- [13] deSouza NM, Reinsberg SA, Scurr ED, Brewster JM, Payne GS. Magnetic resonance imaging in prostate cancer: the value of apparent diffusion coefficients for identifying malignant nodules. *Br J Radiol* 2007;80:90–5.
- [14] Haider MA, van der Kwast TH, Tanguay J, Evans AJ, Hashmi AT, Lockwood G, et al. T2-weighted and diffusion-weighted MRI for localization of prostate cancer. *Am J Roentgenol* 2007;189:323–8.
- [15] Kajihara H, Hayashida Y, Murakami R, Katahira K, Nishimura R, Hamada Y, et al. Usefulness of diffusion-weighted imaging in the localization of prostate cancer. *Int J Radiat Oncol Biol Phys* 2009;74:399–403.
- [16] Riches SF, Payne GS, Morgan VA, Sandhu S, Fisher C, Germuska M, et al. MRI in the detection of prostate cancer: combined apparent diffusion coefficient, metabolite ratio, and vascular parameters. *Am J Roentgenol* 2009;193:1583–91.
- [17] Srodon M, Epstein JI. Central zone histology of the prostate: a mimic of high-grade prostatic intraepithelial neoplasia. *Hum Pathol* 2002;33:518–23.
- [18] Wilm BJ, Gamper U, Henning A, Pruessmann KP, Kollias SS, Boesiger P. Diffusion-weighted imaging of the entire spinal cord. *NMR Biomed* 2009;22:174–81.