



OPEN ACCESS

CASE REPORT

Snap, crackle and pop: when sneezing leads to crackling in the neck

Wanding Yang, Raguwinder S Sahota, Sudip Das

ENT, Head and Neck Surgery,
University Hospitals of Leicester
NHS Trust, Leicester, UK

Correspondence to
Miss Wanding Yang,
dingyang@doctors.org.uk

Accepted 20 December 2017

SUMMARY

Spontaneous perforation of the pharynx is an unusual condition. Due to its non-specific presentation and general lack of awareness, diagnosis and intervention may be delayed resulting in potential complications. This case reports a rare spontaneous perforation of the pyriform sinus after a forceful sneeze, leading to cervical subcutaneous emphysema and pneumomediastinum.

BACKGROUND

Pharyngeal perforation is a condition which often derives from trauma, surgery or infection. It can result in complications without early recognition and treatment. Spontaneous pharyngeal perforation with no identified cause is rare. Here, we report a case of spontaneous pharyngeal rupture after a forceful sneeze, leading to cervical subcutaneous emphysema and pneumomediastinum.

CASE PRESENTATION

A previously fit and well 34-year-old man presented to the emergency department with an acute onset of odynophagia and change of voice after a forceful sneeze. He described a popping sensation in his neck and some bilateral neck swelling after he tried to halt a sneeze by pinching the nose and holding his mouth closed. There was no preceding history of recent iatrogenic procedure or cervical trauma and he denied having eaten anything sharp.

Patient's vital signs were stable on admission with no fever. There was no stridor or other signs of respiratory distress. On physical examination, there was swelling and tenderness especially on the right side of his cervical region. Crepitus was noted in both sides of the anterior neck extending down to the sternum. Fibre-optic nasal pharyngoscopy showed a normal laryngeal appearance with bilateral functioning vocal cords.

INVESTIGATIONS

Lateral soft tissue neck radiograph showed streaks of air in the retropharyngeal region and extensive surgical emphysema in the neck anterior to the trachea (figure 1). Urgent CT of the neck and thorax with contrast confirmed the presence of extensive soft tissue emphysema predominantly centred within the neck as well as pneumomediastinum extending from skull base down to T9 vertebra (figure 2A,B). There was no pneumothorax or evidence of bronchial injury. Lung parenchyma and oesophagus both appeared normal. The

presence of a subtle relative prominence of the right pyriform sinus suggested a possible fistula with the cervical subcutaneous tissue. The air collections were judged as a result from a pharyngeal tear possibly from the right pyriform sinus.

DIFFERENTIAL DIAGNOSIS

Boerhaave's syndrome.

TREATMENT

The patient was admitted due to risk of progression to deep neck infection or even mediastinitis. He was treated conservatively with enteral feeding via a nasogastric tube and prophylactic intravenous antibiotics. His symptoms and subcutaneous emphysema gradually resolved during the course of admission.

OUTCOME AND FOLLOW-UP

A repeat CT neck and thorax with water-soluble contrast swallow 7 days later showed markedly subsided soft tissue emphysema and no evidence of contrast leak. The nasogastric tube was removed and a soft diet was introduced without any problems. The patient was subsequently discharged with advice to avoid obstructing both nostrils while sneezing. On 2 months follow-up, patient did not present any further recurrence or complications.

DISCUSSION

Perforation of the pharynx most commonly result from iatrogenic procedures or blunt neck trauma.¹ Spontaneous pharyngeal perforation can also occur but is relatively rare. The mechanism is thought to involve a sudden rise in intraluminal pressure against closed vocal folds often following coughing, straining, forceful retching or vomiting.² Sneezing, especially with both nostrils and mouth obstructed, is a rare predisposing clinical situation.

In the present case, the rupture site is likely from the right pyriform sinus which suggest the pathophysiology is different from that of Boerhaave's syndrome where the tear tends to involve the distal part of the thoracic oesophagus.³ The pyriform sinus is at risk of perforation during a sudden increase in the pharyngeal pressure due to its lack of a reinforcing longitudinal muscle layer.² In Boerhaave's syndrome, the spontaneous transmural perforation occurs as a consequence of neuromuscular incoordination which leads to failure of the cricopharyngeus muscle to relax.² Although both conditions may present in similar ways with cervical



CrossMark

To cite: Yang W, Sahota RS, Das S. *BMJ Case Rep* Published Online First: [please include Day Month Year]. doi:10.1136/bcr-2016-218906

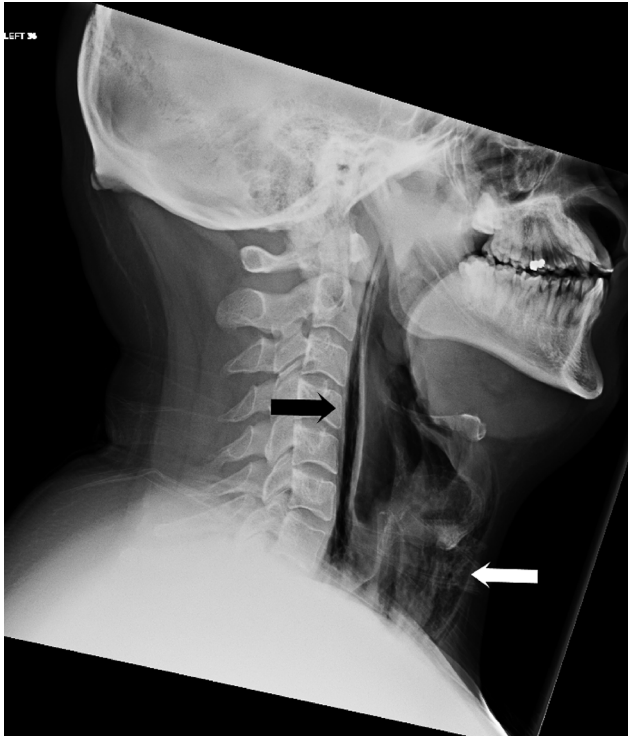

Figure 1 Lateral soft tissue neck radiograph with narrow window setting shows streaks of air in the retropharyngeal region (black arrow) and extensive surgical emphysema in the neck anterior to the trachea (white arrow).

subcutaneous emphysema and spontaneous pneumomediastinum, Boerhaave's syndrome carries a much higher morbidity and mortality and requires prompt and aggressive surgical treatment.³ As the oesophagus ruptures in Boerhaave's syndrome, the gastric contents transgress into the mediastinum resulting in overwhelming mediastinitis, respiratory failure, shock, sepsis and potentially death.³ In contrast, pharynx or pyriform sinus perforation can usually be managed non-surgically and cured without significant morbidity due to its low rate of respiratory or intrathoracic complication.⁴ Patients with well-contained leak and no significant complications can be treated conservatively with enteral/parenteral feeding and broad spectrum antibiotics.

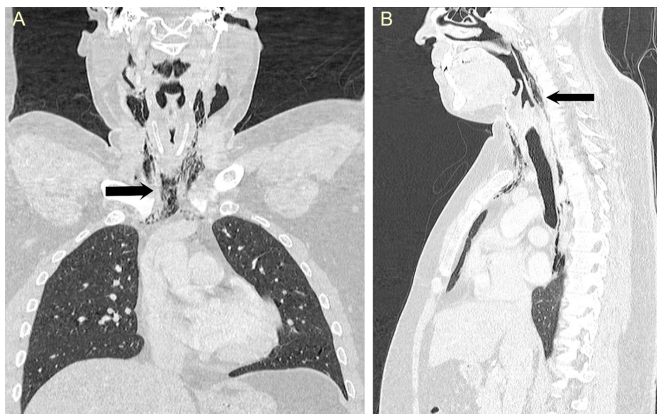


Figure 2 (A and B) Coronal and sagittal CT scan of the neck and thorax showing surgical emphysema within the neck and pneumomediastinum extending from skull base up to T9 vertebra (black arrow).

However, if patients show signs of sepsis or have large perforation, surgical drainage of the paracervical space with or without primary repair is strongly recommended to control the infection and to prevent its expansion into the thorax.⁴

Early diagnosis is often difficult in pharyngeal perforation. Pain is the most common symptoms in perforation of larynx or oesophagus and is usually localised to the site of the perforation.² In our case, the patient presented with an unusual 'popping' sensation over the pyriform sinus immediately after sneezing. It is followed by odynophagia and dysphonia a few hours later. He did not complain of any chest pain which is the most common symptom associated with spontaneous pneumomediastinum. Cervical emphysema is frequent after cervical perforation and can be easily detected with plain X-ray or CT scan. It often descends to cause pneumomediastinum which sometimes can produce Hamman's sign (crackling sound synchronous with the heart beat) when heart beats against air-filled tissue. Nasal endoscopy can occasionally demonstrate the fistula in pharyngeal perforation but it is often difficult as shown in our case. CT scan of the neck and thorax with water-soluble contrast swallow should be used as the gold standard investigation which can confirm the diagnosis and defines the exact pathological site.⁵ In addition, the normal CT appearance of the lung parenchyma and oesophagus helps to exclude more serious causes of pneumomediastinum such as tracheobronchial rupture and Boerhaave's syndrome.

Halting sneeze via blocking nostrils and mouth is a dangerous manoeuvre and should be avoided, as it may lead to numerous complications such as pneumomediastinum, perforation of tympanic membrane and even rupture of cerebral aneurysm.

In conclusion, spontaneous pharyngeal perforation can rarely occur after a forceful sneeze especially against a closed glottis. We should maintain a high degree of suspicion and initiate investigation and treatment early to avoid complication.

Learning points

- ▶ Spontaneous perforation of the pharynx is extremely rare and has a non-specific presentation.
- ▶ The pyriform sinus is at risk of perforation during a sudden increase in the pharyngeal pressure due to its lack of a reinforcing longitudinal muscle layer.
- ▶ Patients with well-contained leak and no significant complications can be treated conservatively.
- ▶ CT scan of the neck and thorax with water-soluble contrast swallow should be used as the gold standard investigation.
- ▶ Simultaneously obstructing both nostrils and mouth during sneezing should be avoided.

Contributors WY and RSS: literature research and cowriter of the manuscript. SD: identified the case and cowriter of the manuscript.

Competing interests None declared.

Patient consent Obtained.

Provenance and peer review Not commissioned; externally peer reviewed.

Open Access This is an Open Access article distributed in accordance with the Creative Commons Attribution Non Commercial (CC BY-NC 4.0) license, which permits others to distribute, remix, adapt, build upon this work non-commercially, and license their derivative works on different terms, provided the original work is properly cited and the use is non-commercial. See: <http://creativecommons.org/licenses/by-nc/4.0/>

© BMJ Publishing Group Ltd (unless otherwise stated in the text of the article) 2018. All rights reserved. No commercial use is permitted unless otherwise expressly granted.

REFERENCES

- 1 Younes Z, Johnson DA. The spectrum of spontaneous and iatrogenic esophageal injury: perforations, Mallory-Weiss tears, and hematomas. *J Clin Gastroenterol* 1999;29:306–17.
- 2 Roh JL, Park CI. Spontaneous pharyngeal perforation after forceful vomiting: the difference from classic Boerhaave's syndrome. *Clin Exp Otorhinolaryngol* 2008;1:174–6.
- 3 Pezzetta E, Kokudo T, Uldry E, *et al.* The surgical management of spontaneous esophageal perforation (Boerhaave's syndrome): 20 years of experience. *Biosci Trends* 2016;10:120–4.
- 4 Shaligram A, Dugar N, Capper R. Perforation of cervical oesophagus. *J Laryngol Otol* 2005;119:51–3.
- 5 Hoskison E, Judd O, Dickinson E, *et al.* Spontaneous pneumomediastinum: benefits of contrast computed tomography imaging. *J Laryngol Otol* 2010;124:220–2.

Copyright 2017 BMJ Publishing Group. All rights reserved. For permission to reuse any of this content visit <http://group.bmj.com/group/rights-licensing/permissions>.
BMJ Case Report Fellows may re-use this article for personal use and teaching without any further permission.

Become a Fellow of BMJ Case Reports today and you can:

- ▶ Submit as many cases as you like
- ▶ Enjoy fast sympathetic peer review and rapid publication of accepted articles
- ▶ Access all the published articles
- ▶ Re-use any of the published material for personal use and teaching without further permission

For information on Institutional Fellowships contact consortiasales@bmjgroup.com

Visit casereports.bmj.com for more articles like this and to become a Fellow