

# Pazopanib, a promising option for the treatment of aggressive fibromatosis

Zoltan Szucs<sup>a</sup>, Christina Messiou<sup>a</sup>, Han Hsi Wong<sup>b</sup>, Helen Hatcher<sup>b</sup>, Aisha Miah<sup>a</sup>, Shane Zaidi<sup>a</sup>, Winette T.A. van der Graaf<sup>a,c</sup>, Ian Judson<sup>a,c</sup>, Robin L. Jones<sup>a,c</sup> and Charlotte Benson<sup>a</sup>

Desmoid tumour/aggressive fibromatosis (DT/AF) is a rare soft-tissue neoplasm that is locally aggressive but does not metastasize. There is no standard systemic treatment for symptomatic patients, although a number of agents are used. Tyrosine kinase inhibitors have recently been reported to show useful activity. We reviewed our bi-institutional (Royal Marsden Hospital, Cambridge University Hospitals) experience with the tyrosine kinase inhibitor pazopanib in the treatment of progressing DT/AF. Eight patients with DT/AF were treated with pazopanib at Royal Marsden Hospital and Cambridge University Hospitals between June 2012 and June 2016. The median age of the patients was 37.5 (range: 27–60) years. The median duration of pazopanib treatment was 12 (range: 5–22) months and for three patients the treatment is ongoing. Three patients discontinued treatment early (patient preference, intolerable toxicity and logistical reasons, respectively). None of the patients showed radiological progression while on treatment, best responses according to Response Evaluation Criteria In Solid Tumors 1.1 were partial response in 3/8 and stable disease in 5/8 cases. Six patients derived clinical benefit from treatment in terms of

improved function and/or pain reduction. Median progression-free survival was 13.5 (5–36) months. Only one patient experienced intolerable toxicity (grade 3 hypertension) leading to early treatment discontinuation. In our series of patients with DT/AF, pazopanib demonstrated important activity both in terms of symptom control (75%) and absence of radiological progression (100%). Results of ongoing confirmatory trials are eagerly awaited. *Anti-Cancer Drugs* 28:421–426 Copyright © 2017 The Author(s). Published by Wolters Kluwer Health, Inc.

*Anti-Cancer Drugs* 2017, 28:421–426

**Keywords:** aggressive fibromatosis, desmoid tumour, pazopanib, tyrosine kinase inhibitor

<sup>a</sup>Sarcoma Unit, The Royal Marsden Hospital NHS Foundation Trust, London, <sup>b</sup>Department of Oncology, Cambridge University Hospitals NHS Foundation Trust, Cambridge Biomedical Campus, Cambridge and <sup>c</sup>The Institute of Cancer Research, Sutton, UK

Correspondence to Charlotte Benson, MB, ChB, MRCP, Sarcoma Unit, The Royal Marsden Hospital NHS Foundation Trust, Fulham Road, London SW3 6JJ, UK

Tel: +44 20 7808 2590; e-mail: charlotte.benson@rmh.nhs.uk

Received 24 September 2016 Revised form accepted 16 December 2016

## Introduction

Desmoid tumour/aggressive fibromatosis (DT/AF) is a rare neoplasm comprising ~3% of all soft-tissue tumours. These low-grade monoclonal proliferations fall within a broad histologic spectrum of fibrous mesenchymal tumours that range from benign proliferations of scar tissue to high-grade fibrosarcomas [1]. DT/AF are unusual in being both highly locally invasive and lacking metastatic potential. Although the clinical course of DTs rarely leads to a fatal outcome, these tumours have a marked propensity to local recurrence and aggressive expansion that can result in significant morbidity and psychological distress [2].

The pathogenesis of DT/AF is complex and several intracellular signalling pathways have been implicated. Higher prevalence in females, during and after pregnancy,

systematic reports of spontaneous regression during menopause support the role of oestrogens in the genesis and maintenance of this disease [3]. Moreover, although sporadic AF does not express oestrogen receptor  $\alpha$ , they display a nearly uniform expression of oestrogen receptor  $\beta$  [4]. *CTNNB1* mutations are described in nearly 85% of cases of sporadic DF/AF, indicating the importance of the Wnt/ $\beta$ -catenin pathway [5]. Indeed, nuclear expression of  $\beta$ -catenin is used as a standard diagnostic test for this disease. Transforming growth factor- $\beta$  is an important promoter of tissue growth and plays a key role in angiogenesis and in fibroblastic proliferations like DT/AF [6,7]. In a minority of cases the disease occurs in patients with a germ-line mutation in *APC*, the gene for classic familial adenomatous polyposis, or Gardner syndrome. DT/AF in Gardner syndrome is more likely to have a truncal site of origin, may develop after surgery and has a worse prognosis than the sporadic type. It is particularly difficult to treat when localized intra-abdominally [8].

Surgery, where technically feasible had until recently been the mainstay of clinical management despite high

This is an open-access article distributed under the terms of the Creative Commons Attribution-Non Commercial-No Derivatives License 4.0 (CCBY-NC-ND), where it is permissible to download and share the work provided it is properly cited. The work cannot be changed in any way or used commercially without permission from the journal.

rates of recurrence and significant post-treatment morbidity [9,10]. However, a number of investigators reported the tendency for the disease to undergo spontaneous stabilization and regression resulting in a revised treatment algorithm such that asymptomatic patients have an initial period of surveillance prior to a decision regarding surgery or systemic treatment [11]. This is now the current standard of care in most European centres [12,13].

In symptomatic patients or in those where tumour growth threatens to compromise mobility or vital structures several nonsurgical medical options may be proposed. Pain is the most frequently mentioned, but often underestimated symptom [13]. First-line systemic therapy is commonly an antioestrogenic agent (i.e. tamoxifen, toremifene) given with or without a NSAID such as celecoxib, sulindac or naproxen [13,14]. The limited toxicity, rare adverse events and low costs of NSAID/antioestrogen treatment are in contrast with the delayed, low response rates seen with this approach [13]. Upon failure of hormonal manipulation or as an alternative first-line option, chemotherapy can also be considered for highly symptomatic patients. Several chemotherapeutic agents, including anthracycline (doxorubicin or pegylated liposomal doxorubicin) or methotrexate/vinca-alkaloid based combinations have been explored with variable success [15,16].

The choice and sequence of systemic treatment is not based on any solid evidence due to a paucity of randomized trials in DT/AF and is often driven by the empirical experience of the treating clinician/institution [12,13]. Radiotherapy is also a viable management option, but there are concerns surrounding late effects including the development of second malignancies which is an important consideration, especially given the young age of onset in most patients [12,13].

In part due to concerns of using cytotoxic drugs in young patients alternative nonchemotherapeutic systemic treatment options have recently been explored. Imatinib was one of the first TKIs showing some initially very promising clinical activity in patients with progressive DF [17]. However, in two more recent prospective, uncontrolled phase II studies [18,19] despite the relatively high

stabilization rates of around 60–80%, rather low objective response rates (3 and 9%, respectively) were observed.

The use of the multitargeted TKI sorafenib resulted in clinical benefit in two-thirds of patients in a retrospective series, with somehow more substantial partial response (PR) and stable disease rates of 25 and 70%, respectively [20]. Importantly, 92% of patients showed features of increased tumour fibrosis and loss of cellularity as demonstrated by a quantifiable early change in MRI T2 signal. In a more recent update [21] on long-term results of 79 patients the objective response rates were slightly lower (17.7%) than the initial report, with a rather impressive median progression-free survival (PFS) of 48.2 months.

Pazopanib is a multitargeted TKI of vascular endothelial growth factor receptors 1, 2 and 3, platelet-derived growth factor receptors  $\alpha$  and  $\beta$  and KIT and is the first such agent to show statistically significant PFS benefit in a phase III trial of pretreated soft-tissue sarcomas [22]. We recently reported our initial pilot results with pazopanib in two patients with DT [23]. These data supported further investigation into the role of pazopanib in DT/AF.

## Patients and methods

We retrospectively analysed the medical records of eight histologically confirmed DT/AF patients who received pazopanib at the Royal Marsden Hospital (six patients) and at Cambridge University Hospitals (two patients) between June 2012 and June 2016. Data were gathered on patient and disease characteristics including symptoms, number and type of prior surgeries, radiation therapy, lines, duration and response to prior systemic therapies (hormonal/NSAID, chemotherapy), dose and toxicities of pazopanib, reason for treatment discontinuation and response to treatment. Radiological assessments were made according to Response Evaluation Criteria In Solid Tumors (RECIST), v1.1. by a consultant radiologist (C.M.) from the Royal Marsden Hospital with expertise in soft-tissue sarcomas. In addition, subjective assessments for changes in signal on T2-weighted MRI were recorded. All patients consented

**Table 1 Patient and pre pazopanib treatment characteristics**

Patient number	Age (male/female)	Site	NSAID + tamoxifen best response and PFS (months)	Anthracycline best response and PFS (months)	Surgery	RT
1	36 (female)	Upper arm	N + T; SD (6)	D × 4; SD (10)	Tenolysis	No
2	40 (female)	Abdominal wall	Intermittent use C + T (NA)	LD × 6; PR (60)	None	No
3	60 (female)	Forearm	C + T; SD (16)	D × 1-drug reaction; NA	Two resections	Yes
4	31 (female)	Abdominal wall	N + T; PD (4)	LD × 6; SD (15)	None	No
5	39 (male)	Upper arm	N + T; PD (3)	None prior to pazopanib	None	No
6	27 (male)	Neck	N + T; SD (7)	LD × 6; PR (19)	Resection	No
7	44 (female)	Chest wall	N + T; SD (10)	LD × 11; SD (12)	None	No
8	17 (female)	Chest wall/axilla	None	LD × 3; SD (3)	None	No

C, celecoxib; D, doxorubicin; LD, liposomal doxorubicin; N, naproxen; NA, not available; PD, progressive disease; PFS, progression-free survival; PR, partial remission; RT, radiotherapy; SD, stable disease; T, tamoxifen.

**Table 2 Pazopanib treatment toxicity profile**

Toxicity	Grade 1	Grade 2	Grade 3
Nausea	3	–	–
Diarrhoea	5	1	1
Stomatitis	2	–	–
Rash	1	–	–
Fatigue	4	2	–
Anorexia	2	–	–
Hypertension	2	–	2
PPE	1	–	–
Transaminitis	3	1	–
GGT elevation	2	–	–
Hyperbilirubinaemia	1	–	–
Wound healing complication	1	–	–

GGT,  $\gamma$ -glutamyl transpeptidase; PPE, palmoplantar erythroderma.

for their clinical data to be processed and published for scientific purposes.

## Results

We treated six females and two males with DT/AF with pazopanib. Median age at the initiation of pazopanib was 37.5 (range: 27–60) years. The main patient and previous (prepazopanib) treatment characteristics of each patient are summarized in Table 1. Primary anatomical sites of DT/AF included the upper arm (two), chest wall (two), abdominal wall (two), forearm (one) and neck (one).

Three patients had a surgical intervention prior to the commencement of pazopanib. Seven patients received prior combined tamoxifen/NSAID treatment. In the 6/7 evaluable patients no objective shrinkage of the tumour was observed, with disease stabilization as best response in four patients; two patients progressed through tamoxifen/NSAID treatment, with no clinical benefit. The median PFS for this treatment option was 6.5 (3–16) months.

In the second line setting seven patients received doxorubicin (pegylated liposomal or standard formulation). In one patient treatment had to be discontinued after one cycle due to a severe drug reaction, therefore, only six patients were evaluable for response to doxorubicin (five received pegylated liposomal doxorubicin, one patient standard doxorubicin) (Table 1). Four patients had

disease stabilization as best response to anthracycline, whereas two patients had a PR. Median PFS of patients on anthracyclines was 13.5 (3–60) months. One patient in our cohort received radiotherapy prior to pazopanib treatment.

Apart from the already listed therapies none of the eight patients received any other systemic treatment or underwent another interventional procedure prior to the initiation of pazopanib.

## Pazopanib treatment and toxicity profile

Pazopanib was initiated on deterioration of clinical symptoms (pain and/or decreased mobility/function) in all eight patients, supported by radiological (according to RECIST) progression of the tumours in 7/8 cases. Pazopanib was started at the standard dose of 800 mg daily and the dose was then titrated according to toxicity, the median final dose of pazopanib being 500 (200–800) mg daily. Pazopanib was administered continuously with no planned treatment breaks, unless excessive toxicity warranted a temporary interruption of treatment.

The most relevant and frequent treatment related toxicities (Table 2) were diarrhoea, fatigue and hypertension. Liver function test changes were all transient and mostly resolved spontaneously. Side effects were generally well controlled with dose adjustments and the support of concomitant anti-diarrheal and antihypertensive drugs. Only 1/8 patients experienced uncontrollable toxicity (grade 3 hypertension) leading to early treatment discontinuation. No grade 4 toxicities were observed.

## Pazopanib treatment outcome

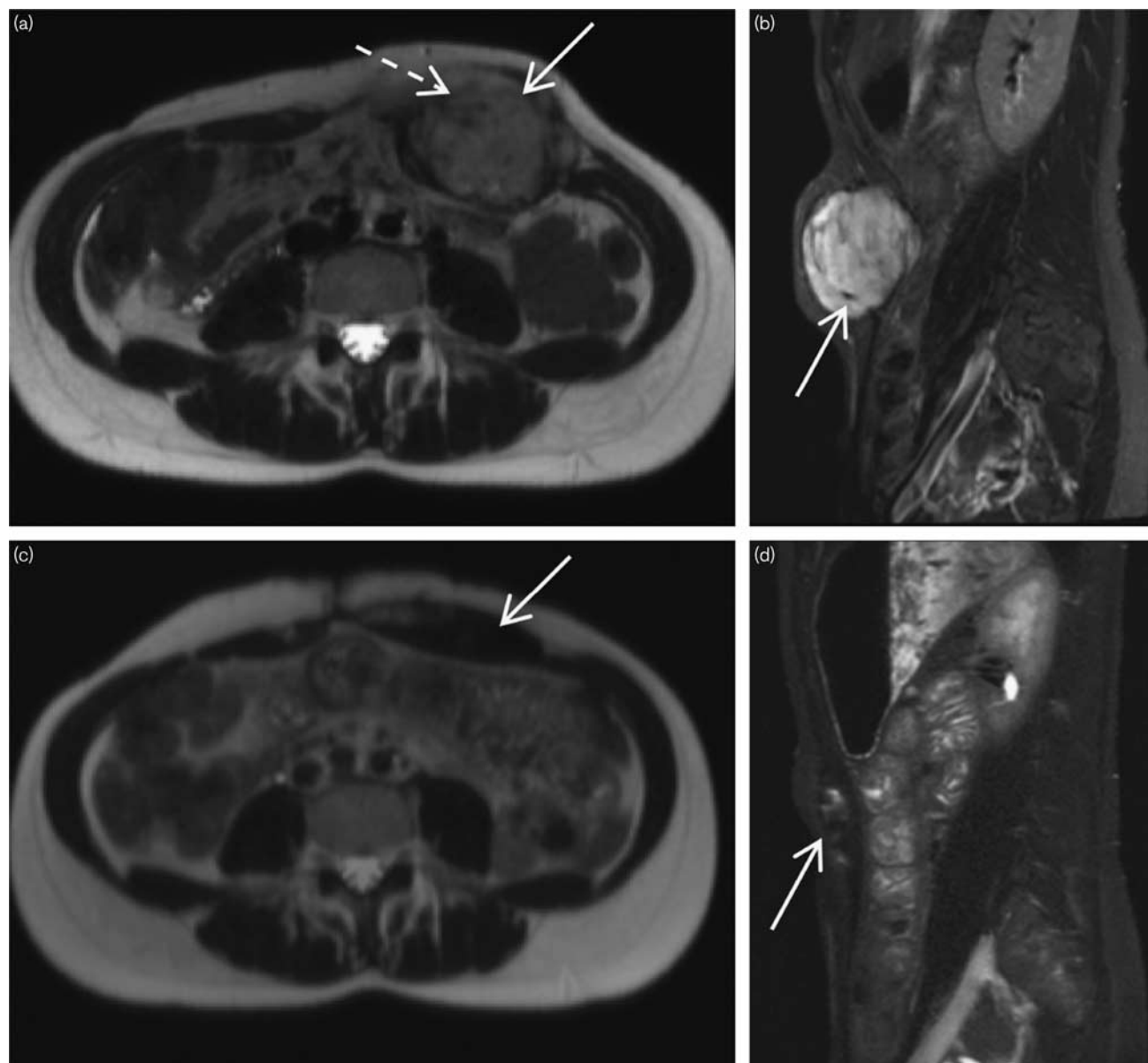
The clinical features of therapy with pazopanib in this series are detailed in Table 3 including duration, type of response and drug toxicities. Median duration of pazopanib treatment was 12 (range: 5–22) months with three patients still on treatment. One patient (patient 1) decided to discontinue pazopanib treatment after 22 months for family planning reasons. One patient (patient 2) had to discontinue pazopanib due to drug cost reimbursement difficulties and was lost to follow-up.

**Table 3 Pazopanib treatment characteristics**

Patient number	Length treatment (months)	Final dose (mg)	Reason for treatment discontinuation	Best response (RECIST 1.1)	Best response (MRI T2-changes)	PFS (months)
1	22	800	Patient's preference	SD	Moderate decrease	36
2	12	400	NHS ineligibility	SD	Moderate decrease	12
3	5	600	Toxicity/intolerance	SD	Stable	15
4	22	60	Still on pazopanib	PR	Marked decrease	22 (ongoing)
5	5	600	Clinical progression-radiological SD	SD	Minor decrease	5
6	12	400	Still on pazopanib	PR	Marked decrease	12 (ongoing)
7	15	200	Still on pazopanib	PR	Marked decrease	15 (ongoing)
8	5	400	Symptomatic progression (pain)	SD	Stable	5

PD, progressive disease; PFS, progression-free survival; PR, partial remission; RECIST, Response Evaluation Criteria In Solid Tumors; SD, stable disease.

Fig. 1



Axial T2-weighted and sagittal short TI inversion recovery MRI of the abdominal wall at baseline (a, b) and following 1 year of treatment (c, d). Baseline images (a, b) demonstrate typical MRI appearances of fibromatosis with intermediate T2 signal tissue containing bands of low signal fibrosis (dashed arrow). Post-therapy scans demonstrate a decrease in size of the left anterior abdominal wall fibromatosis (arrows) but also a drop in T2 signal indicating diminished cellularity.

Best responses (RECIST 1.1) were PR in 3/8 and stable disease in 5/8 cases. Median PFS was 13.5 (range: 5–36) months with more than the third of patients (3/8) still on treatment with an ongoing response. A decrease in MRI T2-weighted signal intensity was observed in 7/8 patients. A marked T2 signal change was seen in all the patients with a RECIST PR (3/3) (Fig. 1). Six (75%) of eight patients derived evident clinical benefit from treatment as defined by a decrease in pain and analgesic

use (in this retrospective study these data were not quantitated with a validated pain scale).

### Conclusion

This report clearly demonstrates that pazopanib is an active treatment option in the management of DT/AF. The lack of effective and well-tolerated therapeutic options and a 'gold-standard' systemic treatment, in conjunction with its high morbidity make DT/AF a

challenging disease. As DT/AF is not strictly considered a malignancy one needs to be careful about treatment recommendations given the life-long risk of complications such as cumulative cardiotoxicity with doxorubicin and second malignancies with chemotherapy and radiotherapy. Chemotherapy and radiotherapy, depending on the disease site, are both potentially damaging to fertility in young patients of reproductive age. TKIs such as pazopanib, have not been reported to have a significant impact on fertility and are unlikely to induce secondary cancers. Antiangiogenic TKIs are of course not without potential detrimental effects on the cardiovascular system, causing hypertension and in some patients a deterioration in left ventricular function; however, these effects appear to be reversible and can usually be managed pharmacologically [24].

Although sorafenib was the first antiangiogenic drug reported to show promising activity in the treatment of DT/AF, it is not a licensed agent for the treatment of soft-tissue sarcomas [17–19]. In contrast, pazopanib (as the only licensed TKI in this setting) has been successfully used for the treatment of soft-tissue sarcomas over the last few years and significant expertise has built up in the management of its toxicities [22]. As our report shows, toxicities of pazopanib were not excessive in most patients and side effects were mainly controllable with dose adjustments. The median daily dose of treatment was significantly lower than in the pazopanib registration study (500 mg in our pilot vs. 722 mg in the PALETTE trial) [22]. Considering the nonmalignant nature of DT/AF and the main aim of treatment is improved symptom management/ quality of life, it is likely the treating physicians were inclined to decrease the dose of the medication. Despite this, pazopanib resulted in durable clinical benefit in our series. In addition, in the retrospective sorafenib series the drug was administered at 400 mg daily dose, which is 50% of the recommended licensed daily dose of the TKI [20,21].

The relative lack of cumulative toxicity of pazopanib compared to standard chemotherapy lends itself to chronic treatment. One question which has not yet been satisfactorily answered with both TKIs (sorafenib and pazopanib) is the optimal duration of therapy and whether long-term treatment is in fact required. Clinical trials will be needed to address this issue.

In our, thus far, limited experience, pazopanib appears to be superior to the commonly used first-line treatment with tamoxifen plus NSAID and compares favourably with the reported activity of sorafenib and pegylated liposomal doxorubicin.

In conclusion, pazopanib is a promising therapeutic option in DT/AF. Our results and the wider clinical context raise the question whether pazopanib should be used in the first-line setting. There is a clear need for prospective data to clearly define the optimal position of

pazopanib in the management of DT/AF. The French Sarcoma Group is currently conducting a randomised phase II trial that assesses the efficacy and tolerance of pazopanib in DT/AF against the active comparator arm being vinblastine plus methotrexate [25]. There is clearly a need to standardize and define the optimal systemic treatment pathway for this rare and often highly morbid disease.

## Acknowledgements

### Conflicts of interest

There are no conflicts of interest.

## References

- Kotligam D, Lazar AJ, Pollock RE, Lev D. Desmoid tumor: a disease opportune for molecular insights. *Histol Histopathol* 2008; **23**:117–126.
- Mendenhall WM, Zlotecki RA, Morris CG, Hochwald DN, Scarborough MT. Aggressive fibromatosis. *Am J Clin Oncol* 2005; **28**:211–215.
- Fiore M, Coppola S, Cannell AJ, Colombo C, Bertagnoli MM, George S, *et al.* Desmoid-type fibromatosis and pregnancy: a multi-institutional analysis of recurrence and obstetric risk. *Ann Surg* 2014; **259**:973–978.
- Deyrup AT, Tretiakova M, Montag AG. Estrogen receptor-beta expression in extraabdominal fibromatoses: an analysis of 40 cases. *Cancer* 2006; **106**:208–213.
- Colombo C, Miceli R, Lazar AJ, Perrone F, Pollock RE, Le Cesne A, *et al.* CTNNB1 45F mutation is a molecular prognosticator of increased postoperative primary desmoid tumor recurrence: an independent, multicenter validation study. *Cancer* 2013; **119**:3696–3702.
- Amini Nik S, Ebrahim RP, van Dam K, Cassiman JJ, Tejpar S. TGF-beta modulates beta-catenin stability and signaling in mesenchymal proliferations. *Exp Cell Res* 2007; **313**:2887–2895.
- Heldin CH, Landstrom M, Moustakas A. Mechanism of TGF-beta signaling to growth arrest, apoptosis, and epithelial-mesenchymal transition. *Curr Opin Cell Biol* 2009; **21**:166–176.
- Bertagnoli MM, Morgan JA, Fletcher CD, Raut CP, Dileo P, Gill RR, *et al.* Multimodality treatment of mesenteric desmoid tumours. *Eur J Cancer* 2008; **44**:2404–2410.
- Smith AJ, Lewis JJ, Merchant NB, Leung DH, Woodruff JM, Brennan MF. Surgical management of intra-abdominal desmoid tumours. *Br J Surg* 2000; **87**:608–613.
- Ballo MT, Zagars GK, Pollack A, Pisters PW, Pollack RA. Desmoid tumor: prognostic factors and outcome after surgery, radiation therapy, or combined surgery and radiation therapy. *J Clin Oncol* 1999; **17**:158–167.
- Bonvalot S, Eldweny H, Haddad V, Rimareix F, Missenard G, Oberlin O, *et al.* Extra-abdominal primary fibromatosis: aggressive management could be avoided in a subgroup of patients. *Eur J Surg Oncol* 2008; **34**:462–468.
- Gronchi A, Colombo C, Le Pechoux C, Dei Tos AP, Le Cesne A, Marrari A, *et al.* Sporadic desmoid-type fibromatosis: a stepwise approach to a non-metastasising neoplasm – a position paper from the Italian and the French sarcoma group. *Ann Oncol* 2014; **25**:578–583.
- Kasper B, Baumgarten C, Bonvalot S, Haas R, Haller F, Hohenberger P, *et al.* Management of sporadic desmoid-type fibromatosis: a European consensus approach based on patients' and professionals' expertise – a sarcoma patients EuroNet and European organisation for research and treatment of cancer/soft tissue and bone sarcoma group initiative. *Eur J Cancer* 2015; **51**:127–136.
- De Camargo VP, Keohan ML, D'Adamo DR, Antonescu CR, Brennan MF, Singer S, *et al.* Clinical outcomes of systemic therapy for patients with deep fibromatosis (desmoid tumor). *Cancer* 2010; **116**:2258–2265.
- Constantinidou A, Jones RL, Scurr M, Al-Muderis O, Judson I. Pegylated liposomal doxorubicin, an effective, well-tolerated treatment for refractory aggressive fibromatosis. *Eur J Cancer* 2009; **45**:2930–2934.
- Weiss AJ, Horowitz S, Lackman RD. Therapy of desmoid tumors and fibromatosis using vinorelbine. *Am J Clin Oncol* 1999; **22**:193–195.
- Heinrich MC, McArthur GA, Demetri GD, Joensuu H, Bono P, Herrmann R, *et al.* Clinical and molecular studies of the effect of imatinib on advanced aggressive fibromatosis (desmoid tumor). *J Clin Oncol* 2006; **24**:1195–1203.
- Penel N, Le Cesne A, Bui BN, Perol D, Brain EG, Ray-Coquard I, *et al.* Imatinib for progressive and recurrent aggressive fibromatosis (desmoid

- tumors): an FNCLCC/French Sarcoma Group phase II trial with a long-term follow-up. *Ann Oncol* 2011; **22**:452–457.
- 19 Kasper B, Grünwald V, Reichardt P, Bauer S, Rauch G, Sommer M, *et al.* Phase II study evaluating imatinib to induce progression arrest in RECIST progressive desmoid tumors not amenable to surgical resection with R0 intent or accompanied by unacceptable function loss – a study of the German Interdisciplinary Sarcoma Group (GISG). *Ann Oncol* 2014; **25**:494.
- 20 Gounder MM, Lefkowitz RA, Keohan ML, D'Adamo DR, Hameed M, Antonescu CR, *et al.* Activity of sorafenib against desmoid tumor/deep fibromatosis. *Clin Cancer Res* 2011; **17**:4082–4090.
- 21 Munhoz RR, Lefkowitz RA, Kuk D, Dickson M, D'Angelo SP, Keohan ML, *et al.* Efficacy of sorafenib in patients with desmoid-type fibromatosis [abstract]. *J Clin Oncol* 2016; **34**:11065.
- 22 Van der Graaf WT, Blay JY, Chawla SP, Kim DW, Bui-Nguyen B, Casali PG, *et al.* EORTC Soft Tissue and Bone Sarcoma Group. PALETTE study group: pazopanib for metastatic soft-tissue sarcoma (PALETTE): a randomised, double-blind, placebo-controlled phase 3 trial. *Lancet* 2012; **379**:1879–1886.
- 23 Martin-Liberal J, Benson C, McCarty H, Thway K, Messiou C, Judson I. Pazopanib is an active treatment in desmoid tumour/aggressive fibromatosis. *Clin Sarcoma Res* 2013; **26**:13.
- 24 Shah RR, Morganroth J. Update on cardiovascular safety of tyrosine kinase inhibitors: with a special focus on QT interval, left ventricular dysfunction and overall risk/benefit. *Drug Saf* 2015; **38**:693–710.
- 25 ClinicalTrials.gov . Pazopanib efficacy and tolerance in desmoids tumors (DESMOPAZ). Identifier: NCT01876082. Available at: <https://clinicaltrials.gov/ct2/show/NCT01876082>. [Accessed 1 September 2016].