

1 TITLE PAGE

2 Correspondence

3 1) Full Title: **Caelyx-induced unilateral erythrodysesthaesia secondary to venous**  
4 **thromboembolism**

5 2) Short Title: as above

6 3) Authors: **Eirini E Merika<sup>(1)</sup>, Martin Gore<sup>(2)</sup>, Louise A. Fearfield<sup>(1,2)</sup>**

7

8 4) Affiliations:

9 <sup>(1)</sup>Department of Dermatology, Chelsea & Westminster Hospital, Fulham Road,  
10 London, SW10 9NH, UK

11 <sup>(2)</sup>Department of Dermatology & Medical Oncology, The Royal Marsden Hospital,  
12 London, UK

13 5) Corresponding author: **Eirini Merika, Dermatology Department, Chelsea &**  
14 **Westminster Hospital, London, UK 020 331 58169,**  
15 [eirini.merika@doctors.org.uk](mailto:eirini.merika@doctors.org.uk)

16 6) manuscript word, table and figure count: 602 (excl. ref), 6 references, 1 figure

17 7) any conflict of interest disclosures: **None**

18

19 **keywords:** erythrodysesthaesia, caelyx, hand foot syndrome, pegylated doxorubicin,  
20 unilateral

21

1

2 **Report:**

3 We report the case of a 52-year old patient who presented with a 2-week history of localised  
4 erythema, swelling and discomfort of the left palm during her 3<sup>rd</sup> cycle of palliative  
5 carboplatin and doxorubicin (Caelyx) for metastatic ovarian cancer. On clinical examination  
6 there was marked unilateral left hand oedema with extensive erythema and early bullae  
7 formation of the palmar aspect consistent with grade 3 erythrodysesthaesia (Fig 1). Very mild  
8 erythema was noted on the right palm. The soles and rest of her skin examination, including  
9 mucosa, were unremarkable. She had had no reaction with her previous two cycles. However  
10 seven days prior to this third cycle she had developed sudden onset of left neck swelling  
11 which was diagnosed on Doppler ultrasound scanning as a deep vein thrombosis (DVT)  
12 affecting the left internal jugular and subclavian veins (Fig. 1b,c). She was treated with very  
13 potent topical steroids, emollients and a soap substitute for the palmoplantar  
14 erythrodysesthaesia and therapeutic enoxaparin injections for the DVT. After a short  
15 treatment break her neck swelling improved and she received a 4<sup>th</sup> cycle which resulted in a  
16 similar but less severe reaction

17 Conventional chemotherapy plays a significant role in cancer management but is often  
18 associated with adverse cutaneous reactions. Pegylated liposomal doxorubicin (PLD) is  
19 widely used in the treatment of solid tumours such as ovarian, breast and AIDS-related  
20 Kaposi's sarcoma. It is characteristically known to cause hand-foot syndrome<sup>1</sup>, also known as  
21 palmar-plantar erythrodysesthaesia (PPE). A similar reaction has been observed with  
22 capecitabine, daunorubicin, sorafenib, 5-fluorouracil and tyrosine-kinase inhibitors.

23 The typical clinical presentation includes symmetrical palmoplantar erythema, swelling and  
24 desquamation. The exact mechanism of the syndrome remains unknown. Drug extravasation

1 due to long-term circulation of metabolically stable pegylated doxorubicin and creation of  
2 reactive oxygen species (pro-inflammatory and directly toxic to the keratinocytes) in the  
3 presence of metal ions in the skin, is thought to be implicated. The drug penetrates capillary  
4 walls very easily and these are concentrated at the fingertips and soles of the feet where the  
5 blood flow is high.

6 Rash development seems to be independent of the number of PLD cycles preceding  
7 chemotherapy regimes. It has been estimated that 77.5% of PPE cases occur within the first 3  
8 infusion cycles. The development of the syndrome has been related to a lower risk of disease  
9 progression and progression-free survival<sup>2</sup>. Tumour cell exposure to PLD was found to be  
10 higher in patients who experienced the rash compared to those without. Therefore rash  
11 development may potentially serve as a surrogate marker for treatment success. This may  
12 have important clinical implications as dose reduction or treatment interruption, because of  
13 rash development, may actually negatively affect treatment outcome in patients that are  
14 actually most likely to benefit.

15 There are no known preventative or treatment strategies; the condition is best treated  
16 symptomatically with potent topical steroids. Some evidence supports the use of 200-400mg  
17 twice daily of celecoxib, a COX-2 non-steroidal anti-inflammatory inhibitor, in the  
18 prevention of PPE development. A zebra-fish model of pegylated liposomal doxorubicin-  
19 induced hand-foot syndrome was recently described in the literature by Chen YH et al; the  
20 group showed reversible skin toxicity upon discontinuation of the drug which may serve as a  
21 screening model for agents managing PPE<sup>3</sup>.

22 Unilateral hand-foot syndrome has only been reported thrice in the literature, following  
23 capecitabine. No imaging to look for associated DVT was documented in the reported cases<sup>4</sup>

24 <sup>6</sup>.

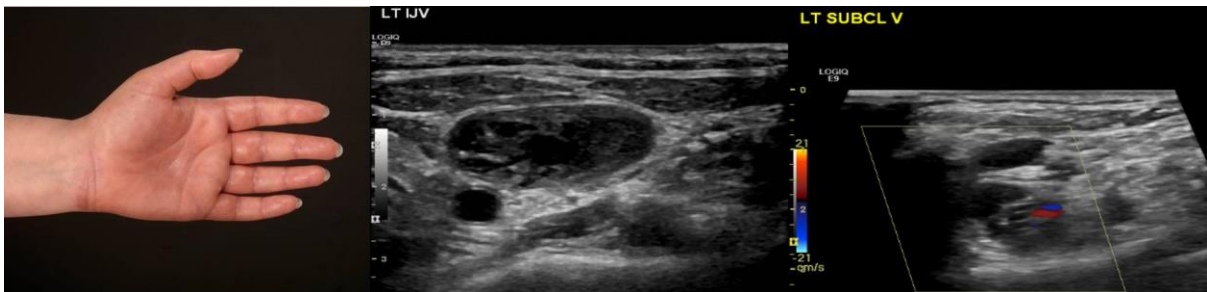
1 To the best of our knowledge, this is the first reported case of caelyx-induced unilateral PPE.  
2 Caelyx is much more frequently associated with PPE and therefore the most likely culprit<sup>7</sup>.  
3 We propose this has occurred because of impaired venous return at the clot level and  
4 therefore higher concentration of a toxic drug in the affected limb with increased the drug  
5 bioavailability and increase toxicity.

6 By reporting DVT as a potential explanation for the rare phenomenon of unilateral PPE we  
7 recommend that clinicians should have a high index of suspicion of thrombo-occlusive events  
8 in patients with malignancy presenting with atypical or unilateral skin reactions.

9

10

11 Figure 1:



12

13 Legend: (a). Grade 3 reaction of the left hand with dysaesthesia, pain, erythema and oedema

14 (b). Thrombus in the left internal jugular vein. (c) Thrombus in the left subclavian vein

15

16

1   References

2

- 3   1.       Reyes-Habito CM, Roh EK. Cutaneous reactions to chemotherapeutic drugs and targeted  
4 therapies for cancer: part I. Conventional chemotherapeutic drugs. *J Am Acad Dermatol* 2014;71:203  
5 e1- e12; quiz 15-6.
- 6   2.       Macedo LT, Lima JP, dos Santos LV, Sasse AD. Prevention strategies for chemotherapy-  
7 induced hand-foot syndrome: a systematic review and meta-analysis of prospective randomised  
8 trials. *Support Care Cancer* 2014;22:1585-93.
- 9   3.       Chen YH, Lee YT, Wen CC, Chen YC, Chen YJ. Modeling pegylated liposomal doxorubicin-  
10 induced hand-foot syndrome and intestinal mucositis in zebrafish. *Onco Targets Ther* 2014;7:1169-  
11 75.
- 12   4.       Disel U, Gurkut O, Abali H, et al. Unilateral hand-foot syndrome: an extraordinary side effect  
13 of capecitabine. *Cutan Ocul Toxicol* 2010;29:140-2.
- 14   5.       Almeida da Cruz L, Hoff PM, Ferrari CL, Riechelmann RS. Unilateral hand-foot syndrome:  
15 does it take sides? Case report and literature review. *Clin Colorectal Cancer* 2012;11:82-4.
- 16   6.       Matsuda S, Koketsu H, Hayakawa M, Nagata N. Unilateral Capecitabine-related Hand-foot  
17 Syndrome. *Intern Med* 2015;54:2779.
- 18   7.       Bast RC, Jr., Markman M. Chemotherapy: A new standard combination for recurrent ovarian  
19 cancer? *Nat Rev Clin Oncol* 2010;7:559-60.

20

21