Annals of Oncology Advance Access published October 25, 2016

Neurotoxicity from immune-checkpoint inhibition in the treatment of melanoma: a single centre experience and review of the literature.

L. Spain[1]*
G. Walls[1]*
M. Julve[1]
K. O'Meara[1]
T. Schmid[1]
E. Kalaitzaki[1]
S. Turajlic[1,2]
M. Gore[1]
J. Rees[3]
J. Larkin[1]**

[1]Melanoma Unit, Royal Marsden NHS Foundation Trust, London, UK
[2]The Francis Crick Institute, London, UK
[3]Neurology Unit, National Hospital for Neurology and Neurosurgery, London, UK

*authors contributed equally
**corresponding authors:
Dr James Larkin,c/o Melanoma Unit, Royal Marsden Hospital, Fulham Road, London SW3 6JJ, United Kingdom; ph: +44 (0)2073528171; james.larkin@rmh.nhs.uk
Dr Jeremy Rees c/o Neurology Unit, National Hospital for Neurology and Neurosurgery, Queen Square, London WC1N 3BG, United Kingdom; ph: +44 (0)8451555000; jeremy.rees@ucl.ac.uk

Downloaded from http://annonc.oxfordjournals.org/ at Institute of Cancer Research on November 20, 2016

Key Message

Immune checkpoint inhibitors as monotherapy and in combination are effective treatments in melanoma. Immune-related side effects may emerge, including neurological toxicity. This rare side effect may be unpredictable and result in major morbidity, but patients may survive for years. We review our experience as well as the literature and provide an approach to management.

© The Author 2016. Published by Oxford University Press on behalf of the European Society for Medical Oncology. All rights reserved. For permissions, please email: journals.permissions@oup.com.

Abstract

Background

Treatment with immune checkpoint inhibitors (ICPi) has greatly improved survival for patients with advanced melanoma in recent years. Anti-CTLA-4 and anti-PD1 antibodies have been approved following large Phase III trials. Immune-related neurological toxicity of varying severity has been reported in the literature. The cumulative incidence of neurotoxicity amongst ipilimumab, nivolumab and pembrolizumab is reported as <1% in published clinical trials. We aimed to identify the incidence of neurotoxicity in our institution across anti-CTLA4 and anti-PD-1 antibodies, including the combination of ipilimumab with nivolumab. We also review the existing literature and propose an investigation and management algorithm.

Methods

All patients with advanced melanoma treated with ipilimumab, nivolumab, pembrolizumab or the combination of ipilimumab and nivolumab (ipi+nivo), managed at the Royal Marsden Hospital between September 2010 and December 2015, including patients on (published) clinical trials were included. Medical records for each patient were reviewed and information on neurotoxicity recorded. A systematic search strategy was performed to collate existing reports of neurological toxicity.

Results

In total, 413 immunotherapy treatment episodes in 352 patients were included, with median follow-up of 26.7 months. Ten cases of neurotoxicity were recorded, affecting 2.8% of patients overall, ranging from grade 1 to 4, affecting both central and peripheral nervous systems. A rate of 14% was noted with ipi+nivo. Three of five patients commenced on corticosteroids responded to these. Six patients had made a full recovery at the time of reporting. A favorable radiological response was found in seven of the ten cases. Unusual presentations are described in detail.

Conclusions

Neurological toxicity is not uncommon, and may be more frequent in patients treated with combination ipi+nivo. Patterns of presentation and response to treatment are varied. A prompt and considered approach is required to optimize outcomes in this group of patients.

Keywords

Immune-related adverse event, neurological toxicity, melanoma, anti-CTLA-4, anti-PD-1

Downloaded from http://annonc.oxfordjournals.org/ at Institute of Cancer Research on November 20, 2016

Introduction

Recent therapeutic advances have substantially improved the prognosis of advanced melanoma. Ipilimumab, nivolumab and pembrolizumab, monoclonal antibodies directed against immune checkpoints, are all approved for treatment and have substantially improved survival outcomes over cytotoxic therapies [1–4]. Nivolumab may be combined with ipilimumab, resulting in the highest response rate and longest progression free survival (PFS) compared to monotherapy with either agent [5]. Ipilimumab also improves recurrence-free survival when used in the adjuvant setting [6].

Toxicity from ICPi occurs due to both upregulation of the immune system and interference with self-tolerance. Rates of moderate and severe immune-related adverse events (irAEs) range from 10-15% for nivolumab and pembrolizumab, 20-30% for ipilimumab and 55% for the combination of ipilimumab and nivolumab (ipi+nivo) [5,7]. Frequently occurring irAEs include dermatitis, colitis, hepatitis, thyroid dysfunction and hypophysitis. Reassuringly the vast majority of toxicity is reversible with corticosteroids and other immune-modulating medication (IMM).

Neurological irAEs are rare, occurring in <1% patients treated in large clinical trials [1-3,5-7]. To date there is limited data available on the incidence of neurotoxicity outside reported clinical trials and most descriptions are contained within anecdotal case reports (see Table S1). Neurological toxicity was not reported in the Checkmate-067 trial [5] and no cases in the literature have been attributed to ipi+nivo yet. The best approach to its management is not defined.

We aimed to review our population of ICPi treated patients with advanced melanoma and identify the frequency of neurological irAEs across all ICPi therapies. We provide vignettes of complex case presentations and their treatment, as well as a proposed algorithm for management, in addition to a review of the available literature.

Methods

We identified all patients with advanced melanoma treated with ipilimumab, nivolumab, pembrolizumab, or ipi+nivo, managed at the Royal Marsden Hospital between September 2010 and December 2015. This included patients on published clinical trials. The medical records for each patient were reviewed and neurological symptoms attributed to ICPi therapy were noted. Where patients had brain or leptomeningeal metastases and a neurological change or decline consistent with this on treatment, we did not record such episodes as drug-related neurological toxicity. Severity was graded according to Common Terminology Criteria for Adverse Events (CTCAE) version 4.0. Information on symptoms, pre-existing neurological or autoimmune conditions, investigations, treatment, need for admission and resolution of symptoms was collected. Descriptive statistics were used to analyse the data whilst the Kaplan-Meier method was used to summarise the overall survival estimates from initiation of treatment to death of any cause. Response to treatment by RECIST version 1.1 was documented in those affected by neurotoxicity. Time to RECIST progression and time to treatment failure (defined as time to next line of therapy or death) were also calculated for the

Downloaded from http://annonc.oxfordjournals.org/ at Institute of Cancer Research on November 20, 2016

patients with neurotoxicity. A systematic search strategy was performed on Pubmed using the terms "ipilimumab", "nivolumab" or "pembrolizumab" and "neurological", "neuropathy", "neurotoxicity", “nervous”, “neuritis”, “meningitis”, “encephalitis”, “encephalopathy” to identify published cases and case series.

Results

There were 352 patients with melanoma who were treated with one or more ICPi from September 2010 until December 2015. In total, there were 413 treatment episodes (ie 61 patients received more than one ICPi). The majority were male (197; 56%) and the median age of the total population was 59 years. Median follow-up in our cohort was 26.7 months (IQR: 13.9 – 37.9 months).Ten episodes of immune-related neurological toxicity were recorded (10/413 treatment episodes, 2.4%; 10/352 patients, 2.8%), ranging from grade 1 to grade 4, and none recurring in the same patient. Three of the 10 cases were attributed to ipi+nivo. Ten patients treated on the Checkmate-067 trial [5] remain blinded to therapy. See Table 1 for frequency by type of ICPi and grade.

Table 1 Frequency and severity of immune-related toxicity by immune checkpoint therapy

Of these ten cases, median age was 67 years (range 51-83), 4 were male. Four of 10 occurred during first-line treatment. Predominantly peripheral nervous system disorders were identified (7/10), of which four were grade 3 or 4. Two of the 10 patients required a prolonged inpatient admission >3months. Corticosteroid therapy was initiated in 5 of the 10 cases, and 3 cases were steroid-responsive. Seven patients made a full recovery, the time to which ranged from 7 to 29 weeks (median 9.4 weeks). Three patients did not have complete resolution of toxicity at the time of this review. Table 2 summarises the clinical details of these 10 cases, the investigations performed and treatment.

In 7 of the 10 patients with neurotoxicity an objective response was noted: 5 with partial response (PR) and 2 with complete response (CR). Six of the10 patients had progressed at the time of this review. The median duration of response was 13.1 months (range 1.0-25.9). Five patients commenced another drug treatment with a median time to treatment failure of 2.9 months (range 1.7-41.0). Several patients meeting criteria for RECIST PD did not require another line of treatment for several months. The median overall survival of patients experiencing neurotoxicity was greater than in the patients who did not develop neurotoxicity: 45.7 months (IQR 45.7m – 45.7m) versus 11.2 months (IQR 4.8m – 36.6m), albeit there were only 10 neurotoxicity cases with 2 deaths amongst them. There was no clear association with conditions such as diabetes mellitus, stroke, hypothyroidism, or previous ICPi therapy, though the prevalence of these factors was low in this group of cases.

Downloaded from http://annonc.oxfordjournals.org/ at Institute of Cancer Research on November 20, 2016

Table 2 Summary of cases of immune-related neurotoxicity at our Institution

Case 1 vignette

A 78-year-old male commenced ipilimumab (3mg/kg) as first-line treatment. One week following the fourth infusion, he presented with subacute right leg weakness developing over one week and impaired sensation of the plantar surface of his feet. Neurological examination revealed moderate weakness in extension and flexion of the hips and knees, dysaesthesia of hands and feet and areflexia of the triceps, knees and ankles. Examination of the CSF revealed raised protein at 0.74g/L, no lymphocytes, normal glucose. MRI of the brain and spine were unremarkable. The patient was admitted for IV steroids with a provisional diagnosis of ipilimumab-related lumbosacral plexopathy. Following 24 hours of twice daily 8mg IV dexamethasone, he deteriorated.

The patient was converted to 2mg/kg IV methylprednisolone and transferred to a tertiary neurology centre. A diagnosis of acute sensorimotor polyradiculoneuropathy (a Guillain-Barre-like syndrome) was made. Motor nerve conduction studies demonstrated proximal demyelinating features but sensory studies were normal. Electromyography demonstrated a mildly reduced interference pattern only. Plasmapheresis was conducted on day five following his presentation due to a lack of clinical improvement with intravenous steroids (discontinued at this point due to plateau in neurological status). However, dysarthria and dysphagia developed within a week of completing plasmapheresis and nasogastric feeding was commenced. At his nadir, 4 weeks after onset, he was paraplegic and had limited use of his arms. Methylprednisolone 1mg/kg was reinstituted and weaned over 2 months. The neuropathy stabilised over the 5th week after symptom onset.

This patient's clinical course was characterised by repeat episodes of pneumonia necessitating ventilation and then a weaning tracheostomy. Re-imaging showed a PR. After 3 months, he regained some power in his legs. Five months from onset the patient's steroids (weaned down to 5mg oral prednisolone 3 months from presentation) were ceased and he was discharged to a neurorehabilitation facility and demonstrates slow, ongoing improvement.

Case 2 vignette

A 79-year-old woman with a past medical history of Graves' disease commenced second-line nivolumab (3mg/kg). She had been treated with ipilimumab 5 months prior and developed grade 3 colitis after cycle 1 requiring 3 months of glucocorticoid therapy and cessation of treatment. One week following cycle 4 nivolumab she presented with malaise and exertional dyspnoea. A comprehensive cardio-respiratory work-up was normal. One week after cycle 5 was due she re-presented with worsening dyspnoea and type 1 respiratory failure. Concurrent dysphagia was managed with nasogastric feeding. Pulmonary function testing revealed paradoxical abdominal motion in addition to low nasal sniff pressures (13cm$H_2$0), attributed to inspiratory muscle weakness. IV methylprednisolone was commenced at 1.5mg/kg daily and in the absence of improvement she was moved to a critical care unit for non-invasive ventilation (NIV) 5 days later.

Downloaded from http://annonc.oxfordjournals.org/ at Institute of Cancer Research on November 20, 2016

Neurological examination revealed fatiguable muscle weakness in the limbs with bulbar dysfunction. Given the similarities with a myasthenic syndrome and lack of improvement with 5 days of methylprednisolone, empirical pyridostigmine was initiated. However a Tensilon test, acetylcholine receptor and neurological paraneoplastic antibodies were negative, as were electromyography and nerve conduction studies (including repetitive nerve stimulation). The working diagnosis was that of nivolumab-induced immune-related phrenic neuropathy resulting in diaphragmatic weakness and a bulbar palsy. After 2 weeks, IV immunoglobulin (IVIg) was commenced due to a plateau in symptoms and the patient clinically improved over the next couple of weeks. IV steroid was switched to oral and the patient was transferred to a specialised respiratory neurorehabilitation centre a month later. She was discharged home, off all corticosteroids, 4 months following initial presentation, and full resolution of symptoms occurred 1 month later. Surveillance imaging demonstrates no new measurable disease at 54 months post-treatment initiation.

Case 3 vignette

A 67-year-old male was commenced on combination ipilimumab (3 mg/kg) and nivolumab (1mg/kg). Two weeks into cycle 1 he was admitted to hospital with new lower back pain associated with paraesthesia of his thighs, constipation, a grade 3 ALT derangement and progressive rash. On examination the lower limbs had reduced power in hip flexion, absent knee but brisk ankle reflexes, and normal plantar responses. Symmetrical loss of fine touch and pain was demonstrated in the T10-L2 dermatomes bilaterally. The patient was commenced on 2mg/kg IV methylprednisolone.

After 48 hours, the left-sided thoracic sensory deficits progressed. Specialist neurology input was sought and a diagnosis of autoimmune bilateral lumbar plexopathy was made, though this did not account for the thoracic-level paraesthesia for which possible transverse myelitis was considered. MRI of the brain and spine were normal however. CSF analysis revealed elevated protein 1.26g/L, lymphocytes and mononuclear cells were noted (white blood cell count: <1 cu. mm.). Matching oligoclonal bands (IgG) were found in the paired serum and CSF samples. Nerve conduction studies were normal. Autoimmune, vasculitis and blood-borne virus screens were normal. On the fifth day there was a substantial improvement in the patient's mobility and sensory deficits, in addition to reduction in the ALT to grade 2, and methylprednisolone was converted to oral prednisolone.

Following intense input from physiotherapy and occupational therapy he was fit for discharge on a reducing dose of prednisolone. At 2 months his neurological symptoms had resolved. Prednisolone was weaned, however the patient has required ongoing low-dose steroids to manage fevers complicating his next-line BRAF-targeted therapy. Surveillance imaging one month following treatment demonstrated an excellent PR to combination immunotherapy. Imaging at two months however indicated disease progression.

Discussion

Downloaded from http://annonc.oxfordjournals.org/ at Institute of Cancer Research on November 20, 2016

Although ICPi have revolutionised the treatment of melanoma, they have given rise to a novel set of adverse effects that require early recognition, appropriate investigation and prompt, careful management. This is the first systematically reported, single-institution series of neurotoxicity across all ICPi treatments in melanoma, including the combination of ipilimumab with nivolumab. We report an overall immune-related neurotoxicity rate of 2.4%, over twice that reported in large phase III clinical trials [1-3, 5-7]. In particular, 14% of patients treated with combination ipilimumab and nivolumab developed a neurological irAE and all of these cases had another concurrent irAE. Despite a median time to symptom resolution of 9.4 weeks in our cohort (noting that some did not resolve), the median survival for this group is very long (45.7 months, CI 13.8-NE) and 70% of patients with neurotoxicity experienced an objective response, durable in 40%. This justifies intensive care and support in the acute treatment and rehabilitation of neurotoxicity in this group of patients.

Two series report immune-related neurotoxicity in 1.5% (11/752) of ipilimumab-treated patients [8] and 3.2% (16/496) of anti-PD-1 treated patients [9], rates similar to our cohort (1% and 3% respectively). Dysgeusia was included in these series (2/11 ipilimumab cases and 1/16 anti-PD-1). We have also summarised the published cases of neurological sequelae secondary to ICPi in Supplementary Table 1. Peripheral neuropathy, Guillain-Barre-like syndromes, cranial nerve palsies, demyelination and myasthenia gravis-type syndromes are all recognised adverse effects [10–12]. There is a bias in the literature towards reporting of neurotoxicity with ipilimumab, likely reflecting its earlier availability. Overall the incidence of irAEs associated with ipilimumab is greater in comparison with anti-PD-1 monotherapy [5, 7]. However, in our series and that of Zimmer et al [9], this does not seem to be the case for neurological toxicity. As anti-PD-1 treatment is continued for a longer duration, there is arguably a greater chance of developing neurological sequelae at a late stage.

Our report presents several cases of neurological toxicity that do not neatly fit the characteristics of 'typical' neurological syndromes, such as in case vignette 3 where the lumbar plexopathy could not account for subjective thoracic sensory changes, and the bilateral phrenic nerve palsy in case vignette 2 associated with bulbar dysfunction. Both peripheral and central nervous systems may be affected and there does not appear to be a clear predominance of one over the other, although in our cohort the peripheral nervous system was more commonly impacted (70% versus 30% cases).

There is a risk of neurological irAEs at any stage throughout the course of treatment with immune-checkpoint agents, however presentations within the first 4 months predominated in our cohort (8/10, 80%). The existing series of ipilimumab and anti-PD-1 neurotoxicity also confirm the predominance of early presentations with only 27% (3/11) patients in the ipilimumab series [8] developing neurological toxicity after 4 months and 25% (4/16) in the anti-PD-1 series [9].

Generally the majority of irAEs can be effectively reversed with corticosteroids and, in keeping with this, it appears that most neurological toxicity is also steroid-responsive (3 of 5 steroid-treated cases in our cohort). However, not all of our patients with neurotoxicity had a clear response to steroids (eg

Downloaded from http://annonc.oxfordjournals.org/ at Institute of Cancer Research on November 20, 2016

case vignettes 1 and 2) and alternative treatments such as IVIg and plasmapheresis may need to be employed in situations with an antibody-mediated pathogenesis. The area of greatest contention with the use of steroids is in Guillain-Barre-like syndromes where corticosteroids in cases of idiopathic onset are not beneficial (but have not been shown to be harmful), but plasma exchange or IVIg initiated within 2 weeks of onset can improve recovery time [13, 14]. It is important to note that allied health practitioners played significant roles in the recovery of neurotoxicity patients managed at our institution. We propose a comprehensive investigation and treatment algorithm (Figure 1A, 1B and 1C) to aid clinicians in managing cases of immune-related toxicity.

Not all patients experience complete resolution of neurotoxicity. Three patients (30%) in our cohort had ongoing symptoms at the time of review. In the ipilimumab series by Voskens et al [8], 5/11 (45%) cases resolved, whereas only 6/16 (38%) cases resolved in the anti-PD-1 treated series by Zimmer et al [9]. The individual duration of follow-up was not clear in these reports and given patients' recovery can take months, such figures may under-represent resolution rates. Looking at case reports is not reliable for such information as there is likely to be a bias towards positive outcomes. Like the immune-related endocrinopathies, neurotoxicity has the potential to cause permanent damage and disability. It should be specifically addressed in informed consent, especially in patients receiving combination ipi+nivo where rates are potentially higher, and in patients receiving adjuvant ICPi therapy. This is particularly important as several patients in our series experienced durable responses and have lived for years.

Although the small numbers preclude any definitive statements, neurotoxicity may be a predictor of response. In our cohort 70% had an objective response by RECIST criteria and many were durable. The objective response rate in the other reported series approximated that of the agents used: 2/11 treated with ipilimumab had a PR [8] and 8/16 had an objective response in the anti-PD-1 treated series [9].

Whilst there is very little data on the specific pathogenesis of immune checkpoint-related neurological toxicity, inflammation around endoneurial microvessels and sub-perineural oedema and inflammation may explain some presentations [15]. PD-1 is also expressed on B cells and blockade has been shown to enhance activation and proliferation [16]. Inhibition of CTLA-4 expressed on certain T helper and T regulatory cells may augment B cell responses and fail to suppress antibody responses [17], thereby also predisposing to antibody-mediated disease.

Limitations

We acknowledge there are limitations within our retrospective review, mostly due to the small number of affected patients from which we cannot draw firm conclusions. Subtle (grade 1) changes may have been under-documented in the medical records. Our overall survival figures are calculated from the first immune checkpoint therapy and some patients may have had prior therapies such as BRAF inhibitors. Unlike the other reports, we did not record dysgeusia as a neurological toxicity. We made

Downloaded from http://annonc.oxfordjournals.org/ at Institute of Cancer Research on November 20, 2016

the assumption that neurological change occurring in the context of progressive central nervous system disease was not a toxicity per se. Ten patients' treatments remain blinded to the authors and therefore their data cannot fully contribute to our conclusions at the time of writing. Nonetheless we feel our data contributes to the small body of literature on this important subject.

Conclusion

Immune-checkpoint inhibition is an established and effective treatment paradigm for patients with metastatic melanoma. As the use of these agents increases in other tumour types it is important for clinicians to be aware of serious potential adverse effects, such as immune-related neurological toxicities, which may have lasting consequences. Whilst these are rare and often responsive to steroid therapy, they can present in a number of patterns, often early in the course of treatment, and unfortunately resolution is not always seen. Thorough neurological examination and access to specialist investigations in order to classify and successfully treat these conditions is important, as many patients have a reasonable chance of long-term disease control. It is clear that further research is required to study the patterns of neurotoxicity, identify the underlying pathogenesis and to optimise the treatment paradigm. Development of an international database would be helpful to further refine management approaches in this complex area.

Downloaded from http://annonc.oxfordjournals.org/ at Institute of Cancer Research on November 20, 2016

Disclosures:

No funding has been received in relation to this manuscript.JL is a non-remunerated consultant for Novartis, Pfizer, BMS, MSD, Roche/Genentech, GSK and Eisai and receives institutional research support from Pfizer, BMS, Novartis and MSD.JL and MG are supported by the National Institute for Health Research Royal Marsden Hospital and Institute of Cancer Research Biomedical Research Centre (NIHR RMH/ICR BRC). ST is a Cancer Research UK (CRUK) Clinician Scientist and is funded by CRUK (Grant Ref C50947/A18176) and the NIHR RMH/ICR BRC(Grant Ref A109). All remaining authors have declared no conflicts of interest.

References

1. Robert C, Long G V, Brady B et al. Nivolumab in previously untreated melanoma without BRAF mutation. N. Engl. J. Med. 2015; 372(4):320–30.
2. Weber JS, D'Angelo SP, Minor D et al. Nivolumab versus chemotherapy in patients with advanced melanoma who progressed after anti-CTLA-4 treatment (CheckMate 037): a randomised, controlled, open-label, phase 3 trial. Lancet. Oncol. 2015; 16(4):375–84.
3. Ribas A, Puzanov I, Dummer R et al. Pembrolizumab versus investigator-choice chemotherapy for ipilimumab-refractory melanoma (KEYNOTE-002): a randomised, controlled, phase 2 trial. Lancet. Oncol. 2015; 16(8):908–18.
4. Robert C, Thomas L, Bondarenko I et al. Ipilimumab plus Dacarbazine for Previously Untreated Metastatic Melanoma. N. Engl. J. Med. 2011; 364(26):2517–2526.
5. Larkin J, Chiarion-Sileni V, Gonzalez R et al. Combined Nivolumab and Ipilimumab or Monotherapy in Untreated Melanoma. N. Engl. J. Med. 2015; 373(1):23–34.
6. Eggermont AMM, Chiarion-Sileni V, Grob J-J et al. Adjuvant ipilimumab versus placebo after complete resection of high-risk stage III melanoma (EORTC 18071): a randomised, double-blind, phase 3 trial. Lancet. Oncol. 2015; 16(5):522–30.
7. Robert C, Schachter J, Long G V et al. Pembrolizumab versus Ipilimumab in Advanced Melanoma. N. Engl. J. Med. 2015; 372(26):2521–32.
8. Voskens CJ, Goldinger SM, Loquai C et al. The price of tumor control: an analysis of rare side effects of anti-CTLA-4 therapy in metastatic melanoma from the ipilimumab network. PLoS One 2013; 8(1):e53745.
9. Zimmer L, Goldinger SM, Hofmann L et al. Neurological, respiratory, musculoskeletal, cardiac and ocular side-effects of anti-PD-1 therapy. Eur. J. Cancer 2016; 60:210–25.
10. Yervoy - Summary of Product Characteristics. [http://www.medicines.org.uk/emc/medicine/24779].
11. Opdivo - Summary of Product Characteristics. [https://www.medicines.org.uk/emc/medicine/30476].
12. Keytruda - Summary of Product Characteristics. [https://www.medicines.org.uk/emc/medicine/30602].

Downloaded from http://annonc.oxfordjournals.org/ at Institute of Cancer Research on November 20, 2016

13. Hughes RAC, Swan A V, van Doorn PA. Intravenous immunoglobulin for Guillain-Barré syndrome. Cochrane database Syst. Rev. 2014; (9):CD002063.
14. Raphaël JC, Chevret S, Hughes RAC, Annane D. Plasma exchange for Guillain-Barré syndrome. Cochrane database Syst. Rev. 2012; (7):CD001798.
15. Manousakis G, Koch J, Sommerville RB et al. Multifocal radiculoneuropathy during ipilimumab treatment of melanoma. Muscle Nerve 2013; 48(3):440–4.
16. Thibult M-L, Mamessier E, Gertner-Dardenne J et al. PD-1 is a novel regulator of human B-cell activation. Int. Immunol. 2013; 25(2):129–37.
17. Sage PT, Paterson AM, Lovitch SB, Sharpe AH. The coinhibitory receptor CTLA-4 controls B cell responses by modulating T follicular helper, T follicular regulatory, and T regulatory cells. Immunity 2014; 41(6):1026–39.

Figure Legend

Figure 1A: Proposed algorithms for investigation and management of neurological toxicity due to immune checkpoint inhibitors, Slide 1

Figure 1B: Proposed algorithms for investigation and management of neurological toxicity due to immune checkpoint inhibitors, Slide 2

Figure 1C: Proposed algorithms for investigation and management of neurological toxicity due to immune checkpoint inhibitors, Slide 3

Downloaded from http://annonc.oxfordjournals.org/ at Institute of Cancer Research on November 20, 2016

Table 1 Frequency and severity of immune-related toxicity by immune checkpoint therapy

	Ipilimumab	Nivolumab	Pembrolizumab	Ipi + Nivo	Blinded*	Total
Number treated	282	27	73	21	10	413
Number with neurotoxicity (%)	3 (1)	2 (7)	1 (2)	3 (14)	1 (10)	10 (2.4)
Grade 1	0	1	1	0	0	2
Grade 2	0	0	0	2	0	2
Grade 3	2	0	0	1	1	4
Grade 4	1	1	0	0	0	2

*treated within the CheckMate-067 trial

Ipi + Nivo = combination ipilimumab and nivolumab

Downloaded from http://annonc.oxfordjournals.org/ at Institute of Cancer Research on November 20, 2016

Table 2 Summary of cases of immune-related neurotoxicity at our Institution

Case &ICPi	Central vs peripheral nervous system	Toxicity	Maximal Grade	Time of onset	Simultaneous non-neuro irAE	Presenting symptoms	Neurological history & potential risk factors	Investigations	Treatment	Time to resolution	Best response (time to best response)	Overall survival from initiation of ICPi
1 Blinded	Peripheral	Motor peripheral neuropathy	3	Cycle 1	None	Weakness of hands and feet and associated functional impairment	Previous stroke	MRI Brain; Nerve conduction studies (NCS; normal)	ICPi discontinued. Oral methylprednisolone 1.5mg/kg (improved)	Significant improvement after 4 months; complete resolution	PR (2.5 months)	Alive after 28 months, with ongoing PR

Downloaded from http://annonc.oxfordjournals.org/ at Institute of Cancer Research on November 20, 2016

2 ipilimumab (vignette #1)	Peripheral	Sensorimotor neuropathy with bulbar palsy (consistent with a Guillain-Barre-like syndrome)	4	Cycle 4	Haematological (neutropenia)	Subacute leg then arm weakness with dysesthesia of feet causing falls	None	Bloods, MRI brain and whole spine, bronchoscopy, lumbar puncture, EMG & NCS *(see details in vignette)*	ICPi discontinued. IV methylprednisolone 2mg/kg (no immediate effect), plasmapheresis (initially stabilised), at nadir methylprednisolone 1mg/kg re-started, required non-invasive ventilation, then tracheostomy	Some improvement after 3 months; ongoing inpatient neurorehabilitation for significant impairment	PR (3.0 months)	Alive after 8 months; ongoing PR
3 ipilimumab	Central	Aseptic meningitis	3	Cycle 2	None	Headache, drowsiness, nausea, vomiting	Previous cisplatin, vincristine and dacarbazine; controlled hypothyroidism	Bloods, lumbar puncture (a few lymphocytes seen), MRI brain	ICPi discontinued. Admission for empirical intravenous cefuroxime, amoxicillin, aciclovir - no infection confirmed; no steroids commenced due to spontaneous improvement	Complete resolution within 10 days	SD (4.3 months)	Died at 46 months; PD at 6 months
4 ipilimumab	Central	Aseptic meningitis	3	Cycle 2	None	Delirium	Previous dacarbazine; previous stroke; controlled hypertension	Bloods, lumbar puncture (normal), MRI brain	ICPi discontinued. Admission for empirical antibiotics but no infective source confirmed. Oral prednisolone (improved); discharged after 2 weeks	Complete resolution in 8 weeks	PD (2.8 months)	Died at 14 months; PD at 3 months
5 pembrolizumab	Peripheral	Peripheral neuropathy	1	Cycle 2	None	Dysesthesiae	None	MRI whole spine	ICPi treatment continued as planned	Ongoing symptoms	PD (1.5 months)	Alive after 21 months; PD through treatment
6 nivolumab	Peripheral	Peripheral neuropathy	1	Cycle 23	Skin	Paraesthesiae	Previous dacarbazine	Bloods	ICPi treatment continued as planned	Complete resolution after 21 weeks	PR (2.1 months)	Alive after 35 months; PD at 23 months
7 nivolumab (vignette #2)	Peripheral	Phrenic nerve palsy with bulbar palsy	4	Cycle 4	Hepatic	Exertional dyspnoea	Previous dacarbazine; past history Grave's disease	Bloods, MRI Brain, echocardiogram, bronchoscopy,	ICPi discontinued. Admission for IV methylprednisolone 1mg/kg (no	Significant improvement after 4 months; complete resolution	CR (7.1 months)	Alive after 54 months; no PD

Downloaded from http://annonc.oxfordjournals.org/ at Institute of Cancer Research on November 20, 2016

								pulmonary function tests, Tensilon test, EMG & NCS *(see details in vignette)*	improvement), pyridostigmine (patient stabilised), IVIg (improvement following further month in ITU), NIV			
8 ipi+nivo (vignette #3)	Peripheral	Bilateral lumbar plexopathy	3	Cycle 1	Hepatic, skin	Lower back pain, proximal weakness and dysesthesiae of thighs	None	Bloods, lumbar puncture, MRI brain, MRI whole spine *(see details in vignette)*	ICPi discontinued. Admission for 2mg/kg IV methylprednisolone (improved)	Complete resolution after 2months	PR (1.6 months)	Alive after 9 months; PD at 2 months
9 ipi+nivo	Peripheral	Sensory (painful) peripheral neuropathy	2	Cycle 7	Pituitary	Paraesthesiae	Previous carotid endarterectomy	Bloods, MRI brain, NCS (normal)	ICPi discontinued. Pregabablin (improved)	Ongoing symptoms	CR (2.6 months)	Alive after 24 months; no PD
10 ipi+nivo	Central	Aseptic meningitis	2	Cycle 1	Hepatic	Headache and nausea	Previous cavernoma	Bloods, lumbar puncture (reactive lymphocytes, neutrophils and monocytes present), MRI brain	Admission for observation only; no infection confirmed; no steroids commenced; C2 ipi+nivo delayed by 4 weeks then continued	Complete resolution at 7 weeks	PR (2.43 months)	Alive after 31 months; PD at 16 months

Downloaded from http://annonc.oxfordjournals.org/ at Institute of Cancer Research on November 20, 2016

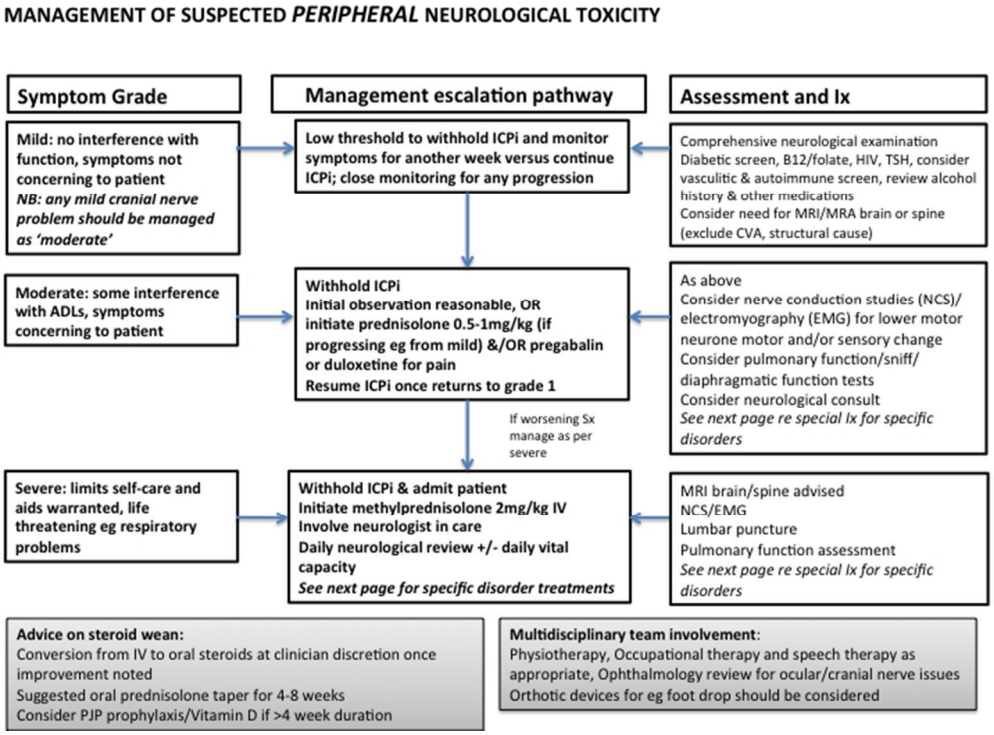

Figure 1: Proposed algorithms for investigation and management of neurological toxicity due to immune checkpoint inhibitors

254x190mm (72 x 72 DPI)

Downloaded from http://annonc.oxfordjournals.org/ at Institute of Cancer Research on November 20, 2016

MANAGEMENT OF SUSPECTED *PERIPHERAL* NEUROLOGICAL TOXICITY

Suspected syndrome	Suggested Investigations	Management approach
Guillain Barre Syndrome (GBS): Progressive symmetrical muscle weakness with absent or reduced tendon reflexes – involves extremities, facial, respiratory and bulbar & oculomotor muscles; dysregulation of autonomic nerves	**Nerve conduction studies** (acute polyneuropathy) **Lumbar puncture** (elevated protein with normal WCC typically) **Pulmonary function tests** with vital capacity and maximum inspiratory/ expiratory pressures **Antibody testing** for GBS variants (eg GQ1b in Miller Fisher variant)	Use of steroids not recommended in idiopathic GBS, however **trial of methylprednisolone 1-2mg/kg reasonable**. Neurological consult. If no improvement or worsening, **plasmapheresis or IVIG** indicated Consider location of care where **ventilatory support** available (required in 15-30% idiopathic cases)
Myasthenia Gravis: Fluctuating muscle weakness (proximal limb, trunk, ocular eg ptosis/diplopia or bulbar) with fatiguability, respiratory muscles may also be involved	Check for ocular muscle and proximal **muscle fatiguability** **Acetylcholine receptor (AChR) and anti-MuSK antibodies** Bedside tests eg Tensilon test or ice pack test with Neurological input **Repetitive nerve stimulation and single fibre EMG**	**Steroids** indicated (oral or IV depending on symptoms) **Pyridostigmine** 30mg TDS Neurological consult. If no improvement or worsening, **plasmapheresis or IVIG** may be considered Additional immunosuppressants azathioprine, cyclosporine, mycophenolate **Avoid certain medications** eg ciprofloxacin, beta-blockers , that may precipitate cholinergic crisis

Other syndromes reported:
Motor and sensory peripheral neuropathy, multifocal radicular neuropathy/plexopathy, autonomic neuropathy, phrenic nerve palsy, cranial nerve palsies (eg facial nerve, optic nerve, hypoglossal nerve).
Steroids suggested as initial management where indicated with neurology specialist input and close attention to potential for respiratory or visual compromise

Figure 1: Proposed algorithms for investigation and management of neurological toxicity due to immune checkpoint inhibitors

254x190mm (72 x 72 DPI)

Downloaded from http://annonc.oxfordjournals.org/ at Institute of Cancer Research on November 20, 2016

MANAGEMENT OF SUSPECTED *CENTRAL* NEUROLOGICAL TOXICITY

Suspected syndrome	Suggested Investigations	Management approach
Aseptic meningitis: *Exclusion of infective causes paramount* Headache, photophobia, neck stiffness with fever or may be afebrile, vomiting; normal cognition/cerebral function (distinguishes from encephalitis	Lumbar puncture- M/C/S (normal Gram stain, WBC<500/microL, normal glucose), PCR for HSV, cytology CNS imaging to exclude brain metastases and leptomeningeal disease	*Exclude bacterial and ideally viral infections prior to high dose steroids* Oral prednisolone 0.5-1mg/kg or IV methylprednisolone 1-2mg/kg if very unwell Consider concurrent empiric antiviral (IV acyclovir) and antibacterial therapy
Encephalitis: *Exclusion of infective & metabolic causes paramount* Confusion or altered behaviour, headaches, alteration in GCS, motor or sensory deficits, speech abnormality, may or may not be febril	Lumbar puncture- M//C/S (normal Gram stain, WBC usually <250/mm3 with lymphocyte predominance, elevated protein but <150mg/dL, usually normal glucose but can be elevated), PCR for HSV & consider viral culture, cytology CNS imaging Consider viral serology	As above for aseptic meningitis Suggest concurrent IV acyclovir until PCR result obtained
Transverse myelitis: Acute or subacute neurological signs/ symptoms of motor/sensory/ autonomic origin; most have sensory level; often bilateral symptoms	MRI brain and spine Lumbar puncture – may be normal but lymphocytosis, elevated protein may be noted, oligoclonal bands not usually present, cytology Serum B12/HIV/syphilis/ANA/anti-Ro & La Ab, TSH, anti-aquaporin-4 IgG	Methylprednisolone 2mg/kg (or consider 1gm/day) Neurology consultation Plasmapheresis may be required if non-steroid responsive

Other syndromes reported:
Neurosarcoidosis, Posterior Reversible Leucoencephalopathy Syndrome (PRES), Vogt-Harada-Koynagi syndrome, Neurosarcoidosis, demyelination, vasculitic encephalopathy, generalised seizures

Figure 1: Proposed algorithms for investigation and management of neurological toxicity due to immune checkpoint inhibitors

254x190mm (72 x 72 DPI)

Downloaded from http://annonc.oxfordjournals.org/ at Institute of Cancer Research on November 20, 2016